

Neuropathological and molecular aspects of low-grade and high-grade gliomas

A. MICHOTTE^{1,4}, B. NEYNS², C. CHASKIS³, J. SADONES⁴ and P. IN 'T VELD⁴

Departments of ¹Neurology and Pathology (Neuropathology), ²Medical Oncology, ³Neurosurgery and ⁴Pathology AZ-VUB

Abstract

Gliomas are the most frequent primary brain tumors. They are derived from glial cells of astrocytic, oligodendroglial and ependymal origin. According to the WHO classification of brain tumors gliomas are divided in low-grade (grades I and II) and high-grade (grades III and IV) tumors. Low-grade tumors are well-differentiated, slow-growing lesions. Grade I tumors are well-circumscribed and often surgically curable, whereas grade II tumors are diffuse, infiltrating lesions with a marked potential over time for progression towards a high-grade malignant tumor. The optimal management of low-grade gliomas is still debated. Important prognostic factors such as histology, grade and location of the tumor, age and functional status of the patient, must be taken into consideration to select the most appropriate treatment. Major advances in the molecular genetic assessment of brain tumors and of gliomas in particular have lead to the identification of several molecular markers playing a crucial role in the development of gliomas and in their malignant transformation. Some of those markers were found very useful to assist in the histological diagnosis and to predict survival and response to therapy. A combined deletion of chromosomes arms 1p and 19q can be found in more than 50% of Grade II and III oligodendrogliomas and has been associated with chemosensitivity and a better prognosis. Once limited to the field of research, molecular biology has now entered the daily neuropathological practice and will undoubtedly play an increasing role in future classification and treatment of brain tumors.

Key words : Neuropathology ; gliomas ; molecular biology ; FISH ; prognosis.

Definition and classification of low-grade gliomas

The most widely used classification and grading of gliomas is that of the World Health Organization (WHO) (Kleihues and Cavenee, 2000). Gliomas are defined pathologically as brain tumors with histological, immunohistochemical and ultrastructural features of glial differentiation. Approximately 50% of primary brain tumors are gliomas, arising from astrocytes, oligodendrocytes or their precursors and ependymal cells. According to the WHO

classification, gliomas are graded on a scale of I to IV based on their degree of malignancy or anaplasia. Grade I and II tumors, the so-called low-grade tumors, are well differentiated slow-growing tumors histologically characterized by a low cellularity, no or rare mitoses and anisonucleosis. Grade I lesions are well circumscribed and therefore entirely surgically removable in most cases without additional therapy. Examples of grade I gliomas include the pilocytic astrocytoma, the subependymal giant cell astrocytoma (SEGA) and the myxopapillary ependymoma. The diffuse infiltrating grade II gliomas can in most cases only be partially treated by surgery and eventually will recur. These diffuse gliomas are classified as astrocytomas, oligodendrogliomas, oligoastrocytomas derived from both astrocytes and oligodendrocytes and ependymomas. Their optimal management is still debated (Whittle, 2004). Although histological benign most of these tumors will transform into malignant grade III and IV tumors within 5-10 years of diagnosis (Maher *et al.*, 2003). Grade III and IV gliomas, the so-called high-grade tumors, are fast growing malignant lesions sharing histological features of anaplasia characterized by a high cellularity, marked anisonucleosis and prominent mitotic activity. Anaplastic astrocytomas, anaplastic oligodendrogliomas and anaplastic oligoastrocytomas are the most frequent grade III tumors. They can develop de novo or from a grade II tumor. Grade IV tumors display in addition signs of endothelial proliferation and/or necrosis (Kleihues and Cavenee, 2000). The glioblastoma is the prototype of the grade IV glioma. Most glioblastomas develop de novo and are called primary glioblastomas. About 25% of them are secondary glioblastomas resulting from the malignant

transformation of a lower grade astrocytoma or less frequently of an oligodendroglioma. The histopathology of glioblastoma is extremely variable (Kleihues and Cavenee, 2000). Usually more or less well differentiated neoplastic astrocytes can be observed at least focally. In the so-called small-cell glioblastoma variant, poorly differentiated small round or fusiform anaplastic cells are the predominant encountered cell type. Histology and grading of gliomas are strong predictors of survival (Kleihues and Cavenee, 2000 ; Behin *et al.*, 2003). Median survival from diagnosis is longer for oligodendrogliomas than for astrocytomas of equal grade (Behin *et al.*, 2003). Age over 40 years, presence of neurological deficits expressed on the Karnofsky performance score and large tumors crossing the midline have a negative impact on prognosis (Pignatti *et al.*, 2002 ; Wessels *et al.*, 2003). The current imaging technique for the evaluation of gliomas is magnetic resonance imaging (MRI). As a rule high-grade tumors often show a prominent gadolinium enhancement, while the grade II gliomas generally lack enhancement. However according to some authors up to one third of high-grade gliomas do not show any contrast enhancement (Scott *et al.*, 2002 ; Wessels *et al.*, 2003). Accurate neuropathological diagnosis is therefore critical for prognostic and therapeutic purposes (Lebrun *et al.*, 2004). Neuropathological evaluation and grading of the tumor may however be difficult even for experienced neuropathologists (Reifenberger and Louis, 2003). Considerable inter-observer variability may indeed exist in the evaluation and grading of astrocytomas, oligodendrogliomas and mixed oligoastrocytomas (Reifenberger and Louis, 2003). Pathological diagnosis must therefore be correlated with clinical and radiological data (Behin *et al.*, 2003). More reliable markers are needed to improve the histological classification and grading of gliomas (Reifenberger and Louis, 2003).

Molecular biology of gliomas

Activation of oncogenes, inactivation of tumor suppressor genes and overexpression of growth factors such as PDGF and EGF are the basic molecular mechanisms of tumor formation and malignant transformation of low-grade tumors (Louis and Cavenee, 2000). Inactivation of the p53 tumor suppressor gene located on chromosome 17p and overexpression of Platelet-derived growth factor (PDGF) and its receptor are two common events occurring early in the formation of grade II astrocytomas (Maher *et al.*, 2003 ; Louis and Cavenee, 2000). Both genetic events are closely linked. Oligodendrogliomas display frequent allelic loss of chromosomes 1p and 19q. These chromosomal abnormalities are found in 50 to 80% of grade II

and grade III tumors suggesting that these alterations are early events in the formation of oligodendrogliomas (Louis and Cavenee, 2000 ; Reifenberger and Louis, 2003). The exact location of oligodendroglioma-associated tumor suppressor genes on 1p and 19q is still unknown. Recently three distinct candidate regions were defined on chromosome 1p (Felsberg *et al.*, 2004). Other molecular markers play a critical role in the transition from low-grade to high-grade gliomas. The transition of grade II astrocytoma to grade III anaplastic astrocytoma is accompanied by allelic losses on chromosomes 9p and 13q (Maher *et al.*, 2003). Chromosome 9p contains the tumor suppressor gene CDKN2/p16. Loss of chromosome 9p is found in approximately 50% of anaplastic astrocytomas and glioblastomas. Another important tumor suppressor gene is the retinoblastoma gene (RB1) mapping to chromosome 13q. RB gene is inactivated in about 20% of AA and 35 % of glioblastomas (Louis and Cavenee, 2000). The dramatic increase in proliferation characteristic for the transition of grade II to grade III astrocytomas is largely related to dysregulation of this RB pathway (Maher *et al.*, 2003). Another progression-associated glial tumor-suppressor gene is located on chromosome 19q13.3. Allelic loss of the long arm of this chromosome is found in 40% of anaplastic astrocytomas and glioblastomas (Louis and Cavenee, 2000). PTEN (phosphatase and tensin homology) gene is a tumor suppressor gene localised on chromosome 10q23. Chromosome 10 loss is a frequent finding in glioblastoma (Louis and Cavenee, 2003). The same genetic alterations (mainly losses of 9p and 13q) are also implicated in the malignant progression of oligodendrogliomas (Maher *et al.* ; 2003, Reifenberger and Louis, 2003 ; Fallon *et al.*, 2004). Molecular studies have lead to the identification of two subsets of glioblastomas with two different underlying molecular pathways (Louis, 1994). Primary glioblastomas occur de novo and are associated in about 40% with an amplification of the oncogene epidermal growth factor receptor (EGFR) located on chromosome 7p12 and loss of chromosome 10q. Secondary glioblastomas result from the malignant progression of a low-grade glioma and display p53/chromosome 17p alterations and PDGF receptor overexpression (Louis and Cavenee, 2000). EGFR gene amplification almost never occurs in tumors with loss of chromosome 17p. Genetic alterations found in oligoastrocytomas resemble either those found in oligodendrogliomas (mainly losses of 1p/19q) or those encountered in diffuse astrocytomas (P53 mutations) (Reifenberger and Louis, 2003). No specific genetic abnormalities for oligoastrocytomas were found. Genetic changes involved in malignant progression of oligoastrocytomas, are similar to those found in other malignant gliomas (losses of 9p, 10q, 13q).

Molecular techniques in neuropathological evaluation of gliomas

Molecular techniques are beginning to be implemented in the daily neuropathological practice. Fluorescence in situ hybridisation (FISH) has emerged as a powerful tool for the assessment of tumoral DNA alterations such as aneusomies, deletions, gene amplifications and translocations (Fuller and Perry, 2002). FISH provides information on DNA localisation and copy number with a high sensitivity and specificity. A major advantage of the technique is that it can also be performed on formalin-fixed tissue allowing examination of archival material. Improved hybridization protocols and the commercial availability of an increasing number of new probes have greatly enhanced the applicability of FISH in the pathology labs. The technique is simple and has much in common with immunohistochemistry. Basic steps of this two-day assay include deparafinization, enzymatic target retrieval, denaturation of probe and target DNA, overnight hybridization, and microscopical analysis and imaging. Probes can be labeled with different fluorophores and can be used simultaneously to detect and quantify different DNA targets. In the case of LOH 1p36, one probe labeled with a green fluorophore directed against the locus 1q25 is combined with a red probe against the locus 1p36. The reference probe allows quantification relative to chromosome 1 copy number and serves as an internal control. Normal nuclei will thus present up to two green and two red signals. In the case of a 1p36 deletion, one red signal is missing (Fig. 1). The diagnosis of LOH1p36 is made when the mean 1p36 / 1q25 ratio (based on 25 hybridizing nuclei) is < 0.8 . Similarly for LOH19q13, a green-labeled reference probe to the locus 19p13 is combined with a red-labeled probe against the 19q13 locus (Fig. 2). In the case of gene amplifications the ratio of target over reference probe is generally > 2.0 . Gene amplifications, such as that of the EGFR gene in glioblastoma multiforme, result in a high copy number of the red-labeled EGFR gene on chromosome locus 7p12 versus the green reference probe directed against the centromeric region of chromosome 7 (Fig. 3). There are also some disadvantages with FISH. Since the minimal size of the probes is at least 30Kb, alterations must be equally large for reliable detection (Fuller and Perry, 2002). Other techniques such as PCR are needed for the detection of smaller alterations (Fuller and Perry, 2002). Another limitation of FISH is that it cannot be used as a genomic screening tool for the identification of new yet unknown alterations. Other techniques are now available for research purposes such as comparative genomic hybridization (CGH), matrixCGH and gene expression microarray chips (Mohr *et al.*, 2002). Microarray technology is a promising tool that allows large-scale assessment

of many genes not only at DNA and RNA level but now also at the level of their protein product (Mohr *et al.*, 2002).

Therapeutic and prognostic implications of genetic alterations

Several retrospective studies have shown that some molecular markers are associated with a longer survival and with a better response to radio- and chemotherapy. The combined deletion of chromosome arms 1p and 19q is found in 50-80% of oligodendrogliomas and has been associated with important prognostic and therapeutic consequences. Genetic analysis of grade II and III oligodendrogliomas with an identical morphology can identify several subgroups with a different response to chemotherapy and a better prognosis (Cairncross *et al.* 1998 ; Ino *et al.*, 2001 ; van den Bent *et al.*, 2003 ; Reifenberger and Louis, 2003 ; Felsberg *et al.*, 2004). Patients whose tumors harbour a combined deletion of chromosomes 1p/19q had a 5-year survival rate of 95% while patients whose tumors lack the 1p deletion had a 17-fold higher risk of death (Cairncross *et al.*, 1998). The same researchers (Ino *et al.*, 2001) identified in their series of 50 patients with a grade III oligodendroglioma four groups of patients. Patients belonging to group 1 (combined 1p/19q deletion without other genetic alterations) had a response rate to chemotherapy of 100% and a median survival of more than 10 years. Patients belonging to group 2 with isolated 1p loss also displayed a 100% response rate to chemotherapy but of shorter duration and a median survival of 6 years. Groups 3 and 4 included patients without 1p/19q loss with a chemosensitivity of only 33% for group 3 and 18% for group 4. The duration of the response to chemotherapy was much shorter in those 2 groups. The tumors of group 3 patients contained p53 mutations. Patients of group 4 lack p53 mutations but instead displayed a genetic profile similar to that of primary glioblastoma (amplification of EGFR gene, loss of 10q). The prognosis in this worst group was similar to that of a glioblastoma with a median survival of 16 months. The significance of 1p/19q loss as a favourable prognostic marker was recently confirmed (Felsberg *et al.*, 2004). Loss of heterozygosity (LOH) on 1p and 19q was in their study associated with a longer survival in patients with low-grade oligodendrogliomas (5-year survival rate of 92% versus 70%). Patients with anaplastic oligodendrogliomas harbouring a combined 1p/19q deletion treated with adjuvant radio- and/or chemotherapy had a 5-year survival rate of 80% versus 36% for those without the deletion. Clinical management of patients with oligodendrogliomas should therefore not only be based on clinical and radiological features, histological diagnosis and grading but should




FIG. 1. — FISH for LOH 1p36 performed on two different oligodendrogliomas show a normal signal distribution with two signals of the green 1q25 reference probe and two signals of the red 1p36 target probe in a single DAPI stained blue cell nucleus of one tumor (Left panel) and a deletion of the 1p36 locus on one chromosome resulting in two green reference signals and a single red target signal in the second tumor (right panel).



FIG. 2. — FISH for LOH 19q13 performed on two different oligodendrogliomas show a normal signal distribution with two signals of the green 19p13 reference probe and two signals of the red 19q13 target probe in a single DAPI-stained blue cell nucleus of one tumor (Left panel) and a deletion of the 19q13 locus on one chromosome resulting in two green reference signals and a single red target signal in the second tumor (right panel).

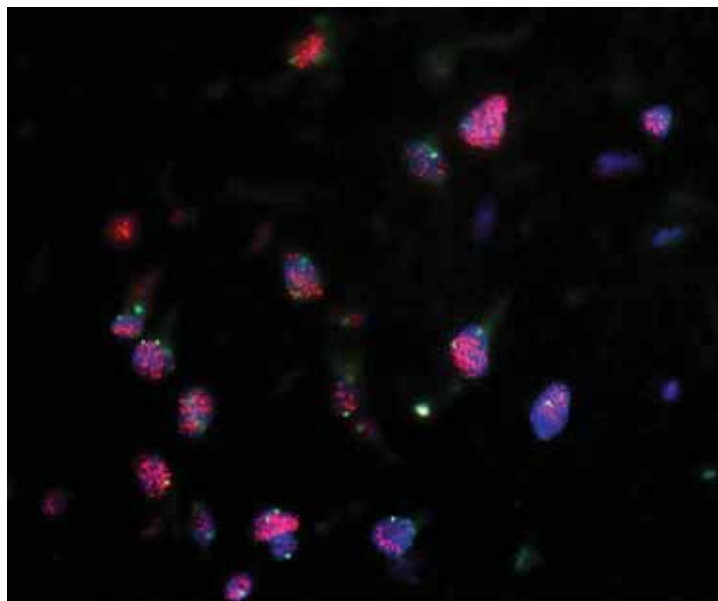


FIG. 3. — FISH for EGFR (red) and the centromere of chromosome 7 (green) on a glioblastoma showing strong EGFR gene amplification as indicated by the large number of red EGFR gene copies versus the green reference probe in multiple DAPI stained blue cell nuclei.

also rely on the molecular characteristics as well (Reifenberger and Louis, 2003). As such molecular genetic characterisation could in a near future play an important role in the selection of those patients who could benefit most from chemotherapy. The most extensively studied first-line chemotherapy for patients with oligodendrogliomas is the combination of procarbazine, lomustine and vincristine (PCV regimen) (Van den Bent *et al.*, 2003). This combination therapy is however associated with cumulative immunosuppression and other serious side effects. Recently Temozolomide (Temodal) has been shown effective as first and second line chemotherapy of oligodendrogliomas (Van den Bent *et al.*, 2001; Van den Bent *et al.*, 2003). Temodal is associated with less side effects and a low incidence of noncumulative hematological toxicity and may improve outcome without affecting significantly the patient's quality of life (Van den Bent *et al.*, 2003). Clinical data are now available supporting the use of chemotherapy in patients with oligodendrogliomas harbouring 1p/19q deletions and with clinical signs of progression. This could potentially allow postponing radiotherapy and its associated risk of delayed cognitive dysfunction (Behin *et al.*, 2003). Another setting where molecular biology has prognostic implications is the glioblastoma. Using FISH amplification of EGFR receptor is found in about 40% of the primary glioblastomas and in less than 10% of anaplastic astrocytomas (Kleihues and Cavenee, 2000). Assessment of EGFR amplification is useful to differentiate small-cell glioblastomas from anaplastic oligodendrogliomas (Reifenberger and Louis, 2003). The presence of EGFR amplification has also been associated with a more rapid progression of the tumor (Louis and Cavenee, 2000). In about half of the glioblastomas with EGFR amplification, the event is coupled with a mutated EGFR, called EGFR variant III (vIII), an aberrant tyrosine kinase (Kleihues and Cavenee, 2000). In a recently presented study, EGFR vIII was detected by immunohistochemistry in 14% of patients with anaplastic astrocytomas and in 20% of the glioblastomas (Bucker *et al.*, 2004). The average survival of vIII positive anaplastic glioma patients was only 7, 2 months, as compared with 33 months for their vIII-negative counterparts. The prognosis of glioblastomas was the same whether the variant was detected or not. EGFR vIII expression was thus significantly associated with reduced survival in grade III tumors but not in patients with glioblastoma.

Conclusion

Molecular markers can predict survival and will play an increasing role in the diagnosis and management of some gliomas. When dealing with grade II and III oligodendrogliomas, diagnostic

testing using FISH technology for 1p and 19q loss should now be offered to the clinician for prognostic and therapeutic purposes. Assessment of EGFR amplification is useful in the evaluation of glioblastomas and for differential diagnosis between small-cell glioblastomas and anaplastic oligodendrogliomas. Detection of the EGFR vIII in anaplastic astrocytomas may identify a subgroup with a prognosis that is comparable to that of glioblastoma.

Acknowledgements

We would like to thank Mrs. Vanessa Ghislain for her skilful technical assistance.

REFERENCES

- BEHIN A., HOANG-XUAN K., CARPENTIER A. F., DELATTRE J. Y. Primary brain tumours in adults. *The Lancet*, 2003, **361** : 323-331.
- BUCKNER J. C., ALDAPE K. D., BALLMAN K., SCHEITHAUER B. W., BURGER P. C. *et al.* Immunohistochemical detection of EGFRvIII and prognostic significance in patients with malignant glioma enrolled in NCCTG clinical trials. *Journal of Clinical Oncology*, 2004, **22**, 14 (Suppl) : 1508.
- CAIRNCROSS J. G., UEKI K., ZLATESCU M. C., LISLE D. K., FINKELSTEIN D. M. *et al.* Specific genetic predictors of chemotherapeutic response and survival in patients with anaplastic oligodendrogliomas. *J. Natl. Cancer Inst.*, 1998, **90** : 1473-1479.
- FALLON B. K., PALMER A. D., ROTH K. A., NABORS L. B., WANG W. *et al.* Prognostic value of 1p, 19q, 9p, 10q, and EGFR-FISH analyses in recurrent oligodendrogliomas. *J. Neuropathol. Exp. Neurol.*, 2004, **63** : 314-322.
- FELSBERG J., ERKWOH A., SABEL M.C., KIRSCH L., FIMMERS R. *et al.* Oligodendroglial tumors : refinement of candidate regions on chromosome arm 1p and correlation of 1p/19q status with survival. *Brain Pathol.*, 2004, **14** : 121-130.
- FULLER C. E., PERRY A. Fluorescence in situ hybridization (FISH) in diagnostic and investigational neuropathology. *Brain Pathol.*, 2002, **12** : 67-86.
- INO Y., BETENSKY R. A., ZLATESCU M. C., SASAKI H., MACDONALD D. R. *et al.* Molecular subtypes of anaplastic oligodendroglioma : Implications for patient management at diagnosis. *Clin. Cancer Res.*, 2001, **7** : 839-845.
- KLEIHUES P., CAVENEE W. K. Pathology and genetic of tumours of the nervous system. Lyon : IARC Press, 2000.
- LEBRUN C., FONTAINE D., RAMAIOLI A., VANDENBOS F., CHANALET S. *et al.* Long-term outcome of oligodendrogliomas. *Neurology*, 2004, **62** : 1783-1787.
- LOUIS D. N. The p53 gene and protein in human brain tumors. *J. Neuropathol. Exp. Neurol.*, 1994, **53** : 11-21.
- LOUIS D. N., CAVENEE W. K. Molecular biology of central nervous system tumors. In : *Cancer : Principles and practice of oncology*. DEVITA V. T., HELLMAN S. (eds.). Lippincott-Raven, Philadelphia, 2000.

- MAHER E. A., FURNARI F. B., BACHOO R. M., ROWITCH D. H., LOUIS D. N. *et al.* Malignant glioma : genetics and biology of a grave matter. *Genes & Development*, 2001, **15** : 1311-1333.
- MOHR S., LEIKAUF G. D., KEITH G., RIHN B. H. Microarrays and cancer keys : an array of possibilities. *Journal of Clinical Oncology*, 2002, **20** : 3165-3175.
- PIGNATTI F., VAN DEN BENT M., CURRAN D., DEBRUYNE C., SYLVESTER R. *et al.* Prognostic factors for survival in adult patients with cerebral low-grade glioma. *J. Clin. Oncol.*, 2002, **20** : 2076-2084.
- REIFENBERGER G., LOUIS D. N. Oligodendroglioma : Toward molecular definitions in diagnostic neuro-oncology. *J. Neuropathol. Exp. Neurol.*, 2003, **62** : 111-126.
- SASAKI H., ZLATESCU M. C., BETENSKY R. A., INO Y., CAIRNCROSS J. G. *et al.* PTEN is a target of chromosome 10q loss in anaplastic oligodendrogliomas and PTEN alterations are associated with poor prognosis. *Am. J. Pathol.*, 2001, **159** : 359-67.
- SCOTT J. N., BRASHER P. M. A., SEVICK R. J., REWCAS-
TLE N. B., FORSYTH P. A. How often are nonenhancing supratentorial gliomas malignant ? A population study. *Neurology*, 2002, **59** : 947-949.
- VAN DEN BENT M. J., KEIME-GUIBERT F., BRANDES A. A., TAPHOORN M. J. B., KROS J. M. *et al.* Temozolomide chemotherapy in recurrent oligodendroglioma. *Neurology*, 2001, **57** : 340-342.
- VAN DEN BENT M., CHINOT O. L., CAIRNCROSS J. G. Recent developments in the molecular characterization and treatment of oligodendroglial tumors. *Neuro-oncology*, 2003, **5** : 128-138.
- WESSELS P. H., WEBER W. E. J., RAVEN G., RAMAEKERS F. C. S., HOPMAN A. H. N. *et al.* Supratentorial grade II astrocytoma : biological features and clinical course. *Lancet Neurology*, 2003, **2** : 395-403.
- WHITTLE I. R. The dilemma of low grade glioma. *J. Neurol. Neurosurg. Psychiatry*, 2004, **75** (Suppl. II).

Dr. A. MICHOTTE,
Dept of Neurology and Pathology,
AZ Vrije Universiteit Brussel,
Laarbeeklaan, 101,
B-1090 Brussel (Belgium).
E-mail : Alex.michotte@az.vub.ac.be.