

## Case reports

# Metastatic medulloblastoma in an adult ; treatment with temozolomide

J. POELEN, H. J. J. A. BERNSEN\* and M. J. J. PRICK

Canisius Wilhelmina Ziekenhuis, Weg door Jonkerbos 100, 6532 SZ Nijmegen, The Netherlands

\* Member of the advisory board of Schering Plough

### Abstract

*Medulloblastoma is a malignant brain tumour most frequently seen in children. Treatment of this tumour type usually consists of surgery followed by radiotherapy. Relapses of medulloblastoma are sensitive to chemotherapy and treatment with chemotherapeutics in children has increased the survival rates. A medulloblastoma at adult age is extremely rare, and there is no overall accepted treatment, especially not in the case of a relapse.*

*Recently improvement of survival was reported in patients with glioblastoma treated with a combination of radiotherapy and concomitant temozolomide.*

*This observation encouraged us to decide to treat an adult patient with a recurrent medulloblastoma with temozolomide. This female patient showed a recurrence of a medulloblastoma 7 years after the initial presentation with metastatic spread along the neuraxis and progressive neurological deterioration. Treatment with temozolomide resulted in relief of clinical symptoms and stabilization of tumour growth for 8 months.*

**Key words :** Medulloblastoma ; temozolomide ; recurrences ; adult ; treatment.

### Introduction

Medulloblastoma is a primitive neuro-ectodermal tumour. It is the second most frequent primary central nervous system tumour seen in childhood (1). The treatment of localized medulloblastoma in children consists of surgery followed by radiotherapy ; in high risk patients chemotherapy is added. Survival in this group of patients depends on the presence of a number of prognostic factors such as metastatic disease, age and a postoperative macroscopic residual disease more than 1.5 cm<sup>2</sup>. The mean survival in children in general is 10 years (2). A medulloblastoma at adult age is very uncommon, comprising only 1% of primary brain tumours (1). The incidence of medulloblastoma in adult patients has risen from 4 per 10<sup>6</sup> person years in '73-'77 to 4.9 per 10<sup>6</sup> person years in '93-'98 (2).

Because a medulloblastoma in adults is a rarity, there are not many studies concerning the treatment of these tumours. Most studies are case reports, the

data are based on retrospective studies and treatments are neither randomized nor uniform.

The therapeutic strategies employed in adults are essentially based on experiences in childhood medulloblastomas and usually consists of surgery followed by radiotherapy. Surgery should be as radical as possible and radiotherapy should contain a boost of at least 55 Gy to the posterior fossa and at least 36 Gy to the craniospinal axis (1).

There is no randomized study concerning adjuvant chemotherapy in the treatment of adults with a medulloblastoma. A definite advantage of adjuvant chemotherapy over radiotherapy can not be demonstrated, but it is currently held that adjuvant chemotherapy may be useful in patients at high risk of recurrence (1). The survival rates in adult patients have improved over the last decades, from a 5-year survival rate between 48% and 65% in the 1980s to a survival rate between 62% and 83% more recently. And although the disease free interval is longer and the survival is greater in adult patients compared to children, innovative therapy is still needed to improve survival when recurrences are present (5).

Recently prolongation of survival was reported in patients with glioblastoma multiforma after treatment with a combination of radiotherapy and concomitant temozolomide (8). There are also indications that this agent has an in vitro anti tumour activity against medulloblastoma cells (3).

We here report the effect of temozolomide in a female patient with a medulloblastoma presented at the age of 26, which recurred 7 years later with metastatic spread in the spinal cord after treatment with surgery and radiotherapy.

### Case report

A previously healthy 26-year-old woman was seen in our neurological clinic with headache, weight loss, nausea and instability during walking. Neurological examination showed some instability during walking. No other neurological abnormalities were seen.

An MR-imaging showed a large tumour attached to the tentorium. Further investigations revealed no

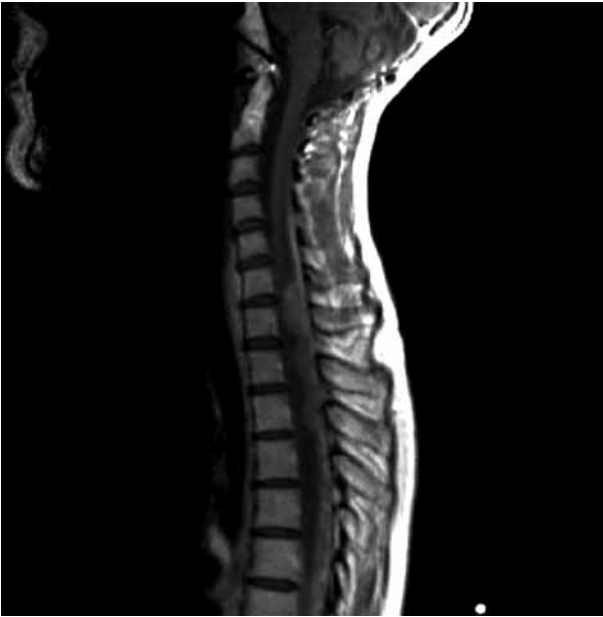

FIG. 1. — T1 weighted sagittal MRI before treatment, showing thoracic and cervical spread of the disease with tumour enhancement.

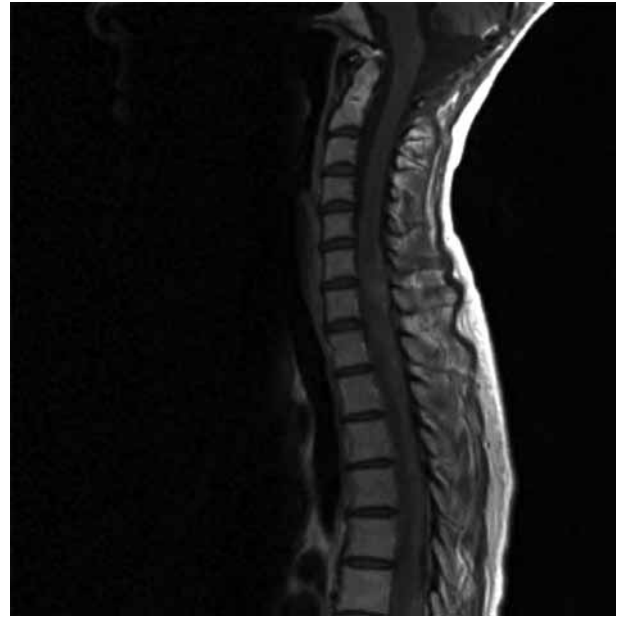


FIG. 2. — T1 weighted sagittal MRI after 4 months of treatment with temozolomide, showing no tumour growth and less tumour enhancement.

evidence of tumour localisation elsewhere. The patient underwent a suboccipital craniotomy and the tumour was macroscopically completely removed and appeared to be a medulloblastoma by pathological examination. She received post-operative craniospinal irradiation with a dose of 35 Gy followed by a boost at the posterior fossa of 20 Gy.

Six years later an MR-imaging showed a relapse of the tumour in the posterior fossa. Again the tumour was surgically removed, and the patient received local irradiation therapy with a dose of 60 Gy at the posterior fossa. After this period of illness she had no complaints at all and she functioned quite normal.

A year later she developed progressive pain and numbness in the legs, neurological examination showed subjective sensory symptoms in the legs and a hyperreflexia. An MR-imaging, showed thoracic and cervical spread of the disease (Fig. 1). A cerebral MR-imaging showed spread of the disease near the lateral ventricles with tumour enhancement. At this point it was decided to start with temozolomide. The initial dose was 225 mg ( $150 \text{ mg/m}^2$ ). The next doses were 350 mg ( $200 \text{ mg/m}^2$ ) each. She received 5 courses in total. After the first course of therapy her pain, which was progressive up to then, disappeared. There were hardly any side effects during the treatment. We did not start steroids.

The next MR-imaging of the cervical and the thoracic spine showed no progression of the tumour and less tumour enhancement (Fig. 2) The MR-imaging of the cerebrum showed a reduction of tumour enhancement. 7 months after initiation of therapy, there was still no progression of the

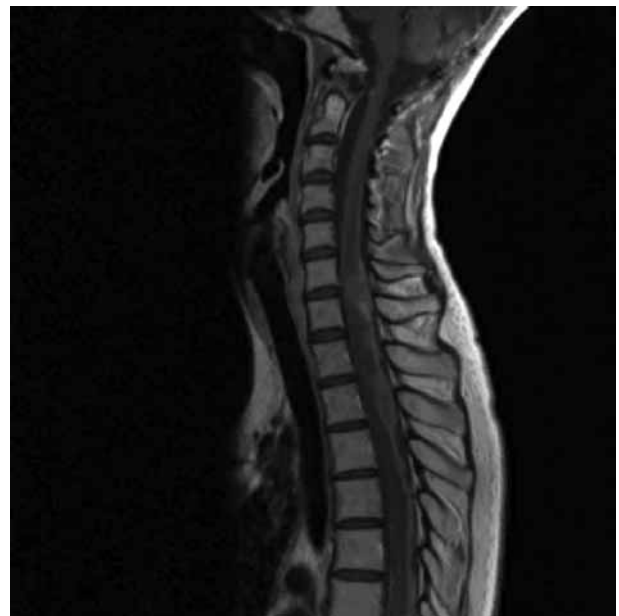

FIG. 3. — T1 weighted sagittal MRI 7 months after the treatment with temozolomide, still showing no progression.

spinal metastasis (Fig. 3). A cerebral MR-imaging showed increasing tumour mass, but no increased tumour enhancement. Eight months after the start of temozolomide, the patient was free of complaints and neurological examination did not show any residual deficits. After 9 months she developed progressive intracerebral disease and was treated with intrathecal cytarabine injections. She died the next month.

## Discussion

In this report we describe the effects of the alkylating agent temozolomide in an adult patient with a recurrent medulloblastoma with spinal cord metastasis after surgery and radiotherapy. For 9 months a stabilisation of the previously progressive disease was observed with improvement of the clinical symptoms.

A medulloblastoma presented in an adult patient is uncommon, and there is no overall accepted treatment strategy. Mostly treatment consists of surgery followed by radiotherapy and in high risk patients adjuvant chemotherapy including cisplatin, etoposide and cyclophosphamide (1, 2).

Herrlinger *et al.* showed a tendency for prolonged survival in patients who received chemotherapy as part of their first-line therapy (5).

Relapses occur frequently in patients with medulloblastomas, the posterior fossa is the most common site of treatment failure. Hazuka *et al.* described 27 adult patients, age 16 years and above, with a cerebellar medulloblastoma. All received surgery, 89% radiotherapy and 48% received also chemotherapy. The median time to relapse was 23.5 months (4). Late recurrences are also described in literature. According to Tabori *et al.* in a study on adolescents with a medulloblastoma, an older age at diagnosis is associated with a longer time to relapse. They also found that female patients had a better event-free-survival (9).

In the case of our patient, the tumour recurred in the posterior fossa 6 years after first presentation and was operatively removed. A year later the tumour relapsed in the spinal axis.

Survival after relapse is very low and currently there is no standard therapy in tumour recurrences in adult patients. It is known that recurrent medulloblastomas are sensitive to chemotherapy and many agents may be useful for palliation. They can induce a high rate of remission for a variable length of time, but they do not cure the patient (1). Herrlinger *et al.* mentioned some indications that second and even third line chemotherapy is reasonable to apply (5). Zia *et al.* showed that the most active chemotherapeutic agents include amongst others cisplatin, carboplatin, etoposide, PCV (procarbazine, CCNU, vincristine), MOPP (nitrogen mustard, vincristine, procarbazine, prednisone). Despite reasonably high response rates of 40-50% with these agents, no long-term disease free survival has been reported there. They describe some improvement in survival rate in 6 patients treated with high-dose chemotherapy and autologous stem cell transplantation (10). Brandes *et al.* mentioned response rates of 41-79% with cisplatin or carboplatin. Friedman *et al.* treated 14 patients with a combination of vincristine and cyclophosphamide; they found a response in 8 out of the 12 patients. Levin *et al.* found a prolonged survival after

aggressive treatment with various forms of chemotherapy. After recurrence 50% was still alive at 2 years and 25% at 3 years (1). However, considerable toxicity should be expected with the above mentioned treatment schedules.

Research into new strategies and chemotherapeutic agents for the treatment of malignant high grade gliomas have led to the synthesis of a new chemotherapy drug, temozolomide. Temozolomide is an oral alkylating chemotherapeutic agent licensed for the treatment of recurrent high-grade gliomas, anaplastic astrocytoma and glioblastoma multiforme.

The anti-tumour-activity of temozolomide is due to methylation of DNA.

It has an oral administration, a low toxicity profile and relatively less side effects. The most significant are nausea, tiredness and haematological side effects such as myelosuppression and neutropenia. In literature, temozolomide has given promising results in the treatment of glioblastoma multiforme. In a recent study, patients with a glioblastoma multiforme additionally treated with temozolomide showed prolonged survival (8).

There are however only three studies concerning the treatment of a recurrent medulloblastoma with temozolomide.

Two reports exist of childhood medulloblastoma treated with temozolomide; Hongeng *et al.* described a 10-year-old boy with a leptomeningeal relapse of a medulloblastoma. He was treated with temozolomide and with good results according to the article (6).

Rao *et al.* described a 31-year-old female with a late cervical relapse of a childhood medulloblastoma who was treated with success with temozolomide (7).

As far as we know only Herrlinger *et al.* mentioned complete remission for 5 and 12 months in two heavily pre-treated adult patients, after the treatment with third line temozolomide (5).

In our patient the tumour relapsed in the spinal cord and the patient progressively deteriorated. We chose to start temozolomide for further treating our patient. Contributing to this choice was the low toxicity profile and the experience in the treatment of glioblastoma multiforme. Our patient received a temozolomide-scheme comparable to the treatment of glioblastoma multiforme. Although the patient died from progressive intracerebral disease, she had shown stabilization of the disease, with resolving clinical symptoms, including the pain, and radiological improvement for 9 months. During the treatment, there were hardly any side effects and the patient functioned very well without any support.

## Conclusion

A medulloblastoma at adult age is very rare and there is no general treatment strategy after

recurrence of this tumour following surgery, radiation therapy and sometimes chemotherapy. Different chemotherapeutic agents can be used for palliation with varying side effects and usually considerable toxicity and different response rates are mentioned. It is therefore still unclear which chemotherapeutic agent to use. In this report we describe the results of treatment with temozolomide in an adult patient with a recurrent medulloblastoma with metastatic spread along the neuraxis. Treatment with temozolomide gave encouraging results, and hardly any side effects. Therefore, we believe that temozolomide should be considered in the treatment options of recurrent and metastatic medulloblastoma in adult patients.

#### REFERENCES

1. BRANDES A. A., PALMISANO V., MONFARDINI S. Medulloblastoma in adults : clinical characteristics and treatment. *Cancer treatment reviews*, 1999, **25** (1) : 3-12.
2. BRANDES A. A., PARIS M. K. Review of the prognostic factors in medulloblastoma of children and adults. *Critical Reviews in Oncology/Hematology*, 2004, **50** : 121-128.
3. FRIEDMANN H. S., DOLAN M. E., PEGG A. E., MARCELLI S., KEIR S. *et al.* Activity of temozolomide in the treatment of central nervous system tumour xenografts. *Cancer Research*, 1995, **55** (13) : 2853-7.
4. HAZUKA M. B., DEBOISE D. A., HENDERSON R. H., KINZIE J. J. : Survival results in adult patients treated for medulloblastoma. *Cancer*, 1992, **15** : 69 (8) : 2143-2148.
5. HERRLINGER U., STEINBRECHER A., RIEGER J., HAU P., KORTMANN R. D. *et al.* Adult medulloblastoma. Prognostic factors and response to therapy at diagnosis and at relapse. *J. Neurol.*, 2005, **252** : 291-299.
6. HONGENG S., VISUDTIBHAN A., DHANACHAI M., LAOTHAMATUS J., CHIAMCHANYA S. Treatment of leptomeningeal relapse of medulloblastoma with temozolomide. *Journal of pediatric haematology/oncology*, 2002, **24** (7) : 591-593.
7. RAO R., ROBINS H., MEHTA M. Late recurrence of a primitive neuro-ectodermal tumour. *Oncology*, 2001, **61** : 189-191.
8. STUPP R., MASON W. P., VAN DEN BENT M. J., WELLER M., FISHER B. *et al.* Radiotherapy plus concomitant and adjuvant Temozolomide for glioblastoma. *The new England Journal of Medicine*, 2005, **352** : 987-96.
9. TABORI U., SUNG L., HUKIN J., LAPERRIERE N., CROOKS B. *et al.* Distinctive clinical course and pattern of relapse in adolescents with a medulloblastoma. *Int. J. Radiation Oncology Biol. Phys.*, 2005, **20** (10) 1-6.
10. ZIA M. I., FORSYTH P., CHAUDHRY A., RUSSELL J., STEWART D. A. Possible benefits of high-dose chemotherapy and autologous stem cell transplantation for adults with recurrent medulloblastoma. *Bone Marrow Transplantation*, 2002, **30** : 565-569.

J. POELEN, M.D.,  
 Canisius Wilhelmina Ziekenhuis,  
 Weg door Jonkerbos 100,  
 6532 SZ Nijmegen (The Netherlands).  
 jpoelen@hotmail.com