



Systemic and non-systemic vasculitis affecting the peripheral nerves

J. FINSTERER

Krankenanstalt Rudolfstiftung, Vienna, Austria, Europe

Abstract

Vasculitis affecting the peripheral nerves predominantly manifests as subacute, progressive, asymmetric sensorimotor polyneuropathy or mononeuritis multiplex, and more rarely as painful mononeuropathy, pure sensory neuropathy, neuropathy of the cranial nerves, plexopathy, or as autonomic neuropathy. Vasculitic neuropathy may occur isolated or non-isolated (systemic) together with involvement of other organs. Systemic vasculitis with involvement of the peripheral nerves is further subdivided into primary (Takayasu syndrome, giant cell arteritis, classical panarteritis nodosa, thrombangitis obliterans, Kawasaki disease, Churg-Strauss syndrome, Wegener granulomatosis, cryoglobulinemic vasculitis, Behcet disease, microscopic polyangiitis, Schoenlein Henoch purpura) or secondary systemic vasculitis (autoimmune connective tissue diseases, vasculitis from infection, sarcoidosis, malignancy, drugs, radiation, or diabetes). In addition to routine laboratory investigations and nerve conduction studies, nerve biopsy is essential for diagnosing the condition and to delineate it from differentials, although its sensitivity is only approximately 60%. Therapy of non-viral vasculitic neuropathy is based on corticosteroids and cyclophosphamide alone or in combination. Additional options include azathioprine, methotrexate, mycophenolate mofetil, or rituximab. In single cases immunoglobulins, immunoadsorption, or plasma exchange have been successfully applied. In case of virus-associated vasculitis interferon-alpha plus lamivudine or ribavirin may be beneficial.

Key words: Immunology, inflammatory disease, rheumatological disease, immune system, immunosuppression, autoimmune disease

Introduction

Vasculitis of the peripheral nervous system (PNS) occurs either in the context of systemic vasculitis or isolated (non-systemic vasculitic neuropathy) (Gorson 2007, Zivkovic *et al.*, 2007). Systemic vasculitis is categorized as either primary, for which there is

no known cause (Takayasu syndrome, giant cell arteritis, classical panarteritis nodosa (PAN), thrombangitis obliterans, Kawasaki disease, Churg-Strauss syndrome (CSS), Wegener granulomatosis, cryoglobulinemic vasculitis, Behcet's disease, microscopic polyangiitis, Schoenlein Henoch purpura) (Table 1), or secondary as a complication of an autoimmune connective tissue disorder, infection, sarcoidosis, malignancy, medication, radiation, or diabetes (Table 2) (Gorson 2007). The course of systemic and non-systemic vasculitic neuropathy may be chronic relapsing, chronic progressive, or monophasic (Schaublin *et al.*, 2005). Vasculitis of the PNS may be classified upon affection of the cranial or spinal nerves, upon affection of motor, sensory, autonomic fibers, or a mixture of these, upon affection of a single or several nerves, affection of small or larger arteries, or upon occurrence of vasculitis with or without involvement of other organs (Table 2). This review aims to give an overview on the current knowledge about the pathogenesis, clinical presentation, diagnosis, treatment, and prognosis of vasculitic neuropathy.

Pathogenesis

Involvement of the PNS in systemic vasculitis results from infiltration of the vasa nervorum or the epineural arteries by inflammatory cells (Pagnoux and Guillemin 2005). Infiltration of the vascular wall facilitates thrombosis and consecutive ischemia. The infiltration is facilitated by breaches in the blood-nerve barrier, which is not as effective as the blood brain barrier. Damage to the blood-nerve-barrier is induced by proinflammatory cytokines, oxidative stress-derived molecules, or metalloproteinases (Pagnoux and Guillemin 2005). Pathologic data are supportive of a primary T-cell mediated immune-pathogenesis (Collins and Periquet, 2004). Altered expression or function of adhesion molecules or

Table 1

Nomenclature of primary systemic vasculitis according to the Chapel Hill Consensus Conference depending on the size of the affected vessels (modified, additionally included were thrombangitis obliterans and M. Behcet)

Large vessel vasculitis
Giant cell arteritis
Granulomatous arteritis of the aorta and its major branches, particularly the extracranial branches of the carotid arteries, usually in patients > 50 y, and associated with polymyalgia rheumatica
Takayasu arteritis
Granulomatous arteritis of the aorta and its major branches, usually affecting patients < 50 y
Medium-sized vessel vasculitis
Classic panarteritis nodosa
Necrotizing vasculitis of the medium- or small-sized arteries
Thrombangitis obliterans (Buerger's disease)
Kawasaki syndrome
Granulomatous vasculitis of large, medium, or small sized arteries, frequently affecting the coronaries, enlarged lymph nodes, usually in children
Small vessel vasculitis
Churg-Strauss syndrome
Wegener's granulomatosis
Cryoglobulinemic vasculitis
Behcet's disease
Microscopic polyangitis
Schoenlein-Henoch purpura
Cutaneous leukocytoclastic vasculitis

leukocyte or endothelial cell activation seem to play a key role in the development of the inflammatory process (Schaublin *et al.*, 2005). The role of anti-neutrophil cytoplasmic antibodies (ANCA) in the pathogenesis of vasculitic neuropathy is unclear (Pagnoux and Guillevin, 2005). Pain in vasculitic neuropathy is believed to be induced by the neurotrophic growth factor, which can be effectively transferred to sensory axons (Yamamoto *et al.*, 2003).

Clinical presentation

The most frequent manifestations of PNS vasculitis are asymmetric, axonal, sensorimotor polyneuropathy (PNP) of acute or subacute onset or progressive, painful multiple mononeuropathy (mononeuritis multiplex), mononeuropathy, pure sensory neuropathy (Seo *et al.*, 2004), plexopathy, cranial neuropathy, or autonomic neuropathy (Gorson 2007; Zivkovic *et al.*, 2007; Burns *et al.*, 2007; Vrancken *et al.*, 2007; Gulturk *et al.*, 2008). More than 50% of the patients present with axonal, sensorimotor PNP (Zivkovic *et al.*, 2007; Oka *et al.*, 2007). Up to 30% of the cases present with mononeuritis multiplex (Zivkovic *et al.*, 2007). A small number of patients (16%) presents with pure sensory abnormalities (Seo *et al.*, 2004; Chao *et al.*, 2007). The prevalence of the other presentations is

unknown. The clinical manifestations of vasculitis vary not only between the types of vasculitis but also within an entity (Table 3). Although any nerve can be affected, most patients have initial symptoms in the tibial or peroneal divisions of the sciatic nerve (Schaublin *et al.*, 2005). In quite a number of patients symptoms are dominated by pain. In about one third of the patients neuropathy is the first and only manifestation of necrotizing vasculitis (Said *et al.*, 2003). In the following sections non-systemic vasculitis of the PNS and systemic vasculitis involving the PNS are described in more detail.

Systemic vasculitis

A. PRIMARY SYSTEMIC VASCULITIS

1. Large vessel vasculitis

Giant cell arteritis

PNS affection is an uncommon but sometimes life-threatening manifestation of giant cell arteritis (Pfadenhauer *et al.*, 2007). Affected patients present with subacute sensorimotor deficits in a cervico-brachial plexus distribution (Pfadenhauer *et al.*, 2007). Compared with stroke or neuro-ophthalmologic complications in giant cell arteritis, PNS involvement in form of vasculitic neuropathy is much rarer (Pfadenhauer *et al.*, 2007).

Table 2
Conditions associated with vasculitis of the peripheral nervous system

Disorder	FPI	Reference
Systemic vasculitis		
A. Primary		
Giant cell arteritis	Rare	(Pfadenhauer <i>et al.</i> , 2007; Fineles and Arnold, 2007)
Classical panarteritis nodosa	35-75%	(Schaublin <i>et al.</i> , 2005; Kostina-O'Neil <i>et al.</i> , 2007)
Thrombngitis obliterans (Buerger disease)	Rare	(Vincent <i>et al.</i> , 1985)
Kawasaki syndrome	1 patient	(Hicks <i>et al.</i> , 1982)
Churg-Strauss syndrome	65-80%	(Zwerina <i>et al.</i> , 2008; Djukic <i>et al.</i> , 2008)
Wegener granulomatosis	14-50%	(Schaublin <i>et al.</i> , 2005; Feuerlein <i>et al.</i> , 2008)
Cryoglobulinemia	30-70%	(Schaublin <i>et al.</i> , 2005; Cacoub <i>et al.</i> , 2008)
M. Behcet	20%	(Gulturk <i>et al.</i> , 2008)
Microscopic polyangitis	6-70%	(Schaublin <i>et al.</i> , 2005)
Schönlien-Henoch purpura	Rare	(Bulun <i>et al.</i> , 2001; Ohnuma <i>et al.</i> , 2008)
B. Secondary		
1. Mixed connective tissue disease		
Systemic lupus erythematosus	27%	(Servioli <i>et al.</i> , 2007; Shoshtary <i>et al.</i> , 2005)
Rheumatoid arthritis	50%	(Schaublin <i>et al.</i> , 2005; Muramatsu <i>et al.</i> , 2008)
Sjögren syndrome	45%	(Terrier <i>et al.</i> , 2007; Iopate Lopate <i>et al.</i> , 2006)
2. Infection		
Hepatitis C	Unknown	(Said and Lacroix, 2005; Cacaoub <i>et al.</i> , 2008)
Streptococcal infection	Unknown	(Traverso <i>et al.</i> , 1997)
HIV	< 1%	(Schaublin <i>et al.</i> , 2005)
Cytomegaly virus	Rare	(Schaublin <i>et al.</i> , 2005)
Histoplasmosis	Rare	(Berry <i>et al.</i> , 1999)
Lues	Rare	(Mathew <i>et al.</i> , 2007)
3. Sarcoidosis	47%	(Said and Lacroix, 2005; Vital, 2008; Allen <i>et al.</i> , 2003)
4. Medication	Rare	(Schapira <i>et al.</i> , 2008)
5. Malignancy	32%	(Schaublin <i>et al.</i> , 2005; Fain <i>et al.</i> , 2007)
6. Radiation	1 patient	(Rubin <i>et al.</i> , 2001)
7. Diabetic/non-diabetic plexopathy	Not applicable	(Schaublin <i>et al.</i> , 2005; Said and Lacroix, 2005)
Non-systemic vasculitis	Not applicable	(Said and Lacroix, 2005)

FPI: frequency of PNS involvement.

Table 3
Frequent clinical presentations of neuropathy in some types of primary systemic vasculitis

	smPNP	MonMP	MoNP	CN	sNP	aNP	Plexopathy
GCA	x						x
PAN	x	x	x	x			
Thrombangitis				x		x	
Kawasaki	x						
CSS	x	x	x	x	x		
Wegener	x	x		x		(x)	
Cryoglobulinaemia	x	x		x	x	x	
Behcet	x	x	x	x	x	x	
Microscopic polyangitis	x	x	x	x			
Schoenlein Henoch	x	x	x				

GCA: giant cell arteritis, PAN: classical panarteritis nodosa, smPNP: sensorimotor polyneuropathy, MonMP: mononeuritis multiplex, MoNP: mononeuropathy, CN: cranial nerve involvement, sNP: sensory neuropathy, aNP: autonomic neuropathy.

2. *Medium vessel vasculitis*

Classical panarteritis nodosa

Classical PAN is a rare systemic vasculitis of the small or medium-sized arteries without affection of arterioles, capillaries, or venules, affecting all organs (Schaublin *et al.*, 2005; Harada *et al.*, 2000). Viruses or bacteria, particularly streptococcus and hepatitis B, are assumed to be implicated in the pathogenesis of the disease. PAN is the systemic vasculitis most frequently associated with viral infection, particularly with hepatitis-B virus. One third to one half of the cases are associated with hepatitis B (Schaublin *et al.*, 2005). In up to 75% of the patients with classical PAN vasculitic neuropathy occurs (Schaublin *et al.*, 2005). Thus, classical PAN is one of the types of systemic vasculitis most frequently associated with vasculitic neuropathy. In cases of PNS involvement, patients present with painful mononeuritis multiplex (Hagiwara *et al.*, 2003) or sensory ataxic neuropathy (Harada *et al.*, 2000). In single cases the presentation may mimic chronic inflammatory demyelinating PNP (CIDP) (Tanaka *et al.*, 1998).

Buerger's disease (thrombangitis obliterans)

Thrombangitis obliterans is characterized by vasculitis of the small and medium-sized arteries of the lower arms and the lower legs. Men are more frequently affected than women. Involvement of the cerebrum, intestines, or the heart is rare. The typical finding of necrotizing vasculitis, fibrinoid necrosis, is absent in thrombangitis obliterans. In a single patient ischemic optic neuropathy has been reported as a manifestation of the disease (Coppeto and Adamczyk 1988). In another patient microvasculitis of nerve and muscle have been observed (Vincent *et al.*, 1985).

Kawasaki disease

Kawasaki disease is an acute, self-limiting vasculitis of unknown etiology. The intense inflammatory process has a predilection for the coronary arteries (Wood and Tulloh 2008). Only in a single patient Kawasaki disease was associated with sensorimotor PNP (Hicks *et al.*, 1982). Whether PNP in this patient was due to vasculitis or of other origin remains speculative.

3. *Small vessel vasculitis*

Churg-Strauss syndrome

Churg-Strauss syndrome (CSS) is a systemic, granulomatous vasculitis of the small and medium-sized arteries, arterioles, capillaries, or venules, characterized by infiltration of eosinophils. At onset

patients present with asthma, allergic rhinitis, fever, or eosinophilia. They later develop eosinophilic infiltrates in the lung and the intestines, followed by systemic vasculitis. ANCA are elevated in some of the patients (Zwerina *et al.*, 2008). Involvement of the PNS occurs in 65-80% of the cases (Schaublin *et al.*, 2005) and usually manifests as mononeuritis multiplex, pure sensory neuropathy, or may progress into axonal sensorimotor PNP in the later stages (Chao *et al.*, 2007; Hattori *et al.*, 1999). In a study on 26 patients with CSS 15 (58%) developed vasculitic neuropathy (Cattaneo *et al.*, 2007). Vasculitic neuropathy in these patients occurred earlier and was more severe than in patients with Wegener's granulomatosis (Cattaneo *et al.*, 2007). Children have less frequently vasculitic PNP than adults (Zwerina *et al.*, 2008). In half of the patients vasculitis is histologically of the necrotizing type (Hattori *et al.*, 1999). Because of the high prevalence of vasculitic neuropathy in CSS, it is one of the diagnostic criteria for CSS.

Wegener granulomatosis

Wegener granulomatosis is a systemic, necrotizing vasculitis of the capillaries, arterioles, or venules associated with granuloma formation in the upper and lower respiratory tract (Schaublin *et al.*, 2005). About 80% of the patients develop glomerulonephritis, but principally each organ can be affected. c-ANCA are usually elevated. Vasculitis neuropathy occurs in about one third of the patients (14-40%) (Schaublin *et al.*, 2005). In a cohort study on 26 patients with Wegener's granulomatosis 6 (23%) developed vasculitic neuropathy (Cattaneo *et al.*, 2007). Most frequently vasculitic neuropathy manifests as mononeuritis multiplex (Cattaneo *et al.*, 2007) or rarely as mononeuropathy of a cranial nerve (Marsot-Dupuch *et al.*, 2002) or sensorimotor PNP (Dickey and Andrews, 1990). Vasculitic neuropathy is usually less severe than in patients with CSS (Cattaneo *et al.*, 2007). Neuropathy may be even the initial manifestation of the disease (Pleasure, 2001). Vasculitic neuropathy in patients with Wegener's granulomatosis is of the axonal type (Jimenez-Medina and Yablon 1992). Usually, neuropathy develops within 2 y of diagnosis (Schaublin *et al.*, 2005).

Cryoglobulinemia

Elevated cryoglobulin levels may develop secondary to chronic infection, autoimmune disease (in 16% of patients with rheumatoid arthritis) (Said and Lacroix, 2005), or hematologic disease (Schaublin *et al.*, 2005). Cryoglobulinemia either remains asymptomatic or causes immune-complex mediated systemic vasculitis, mainly affecting the small

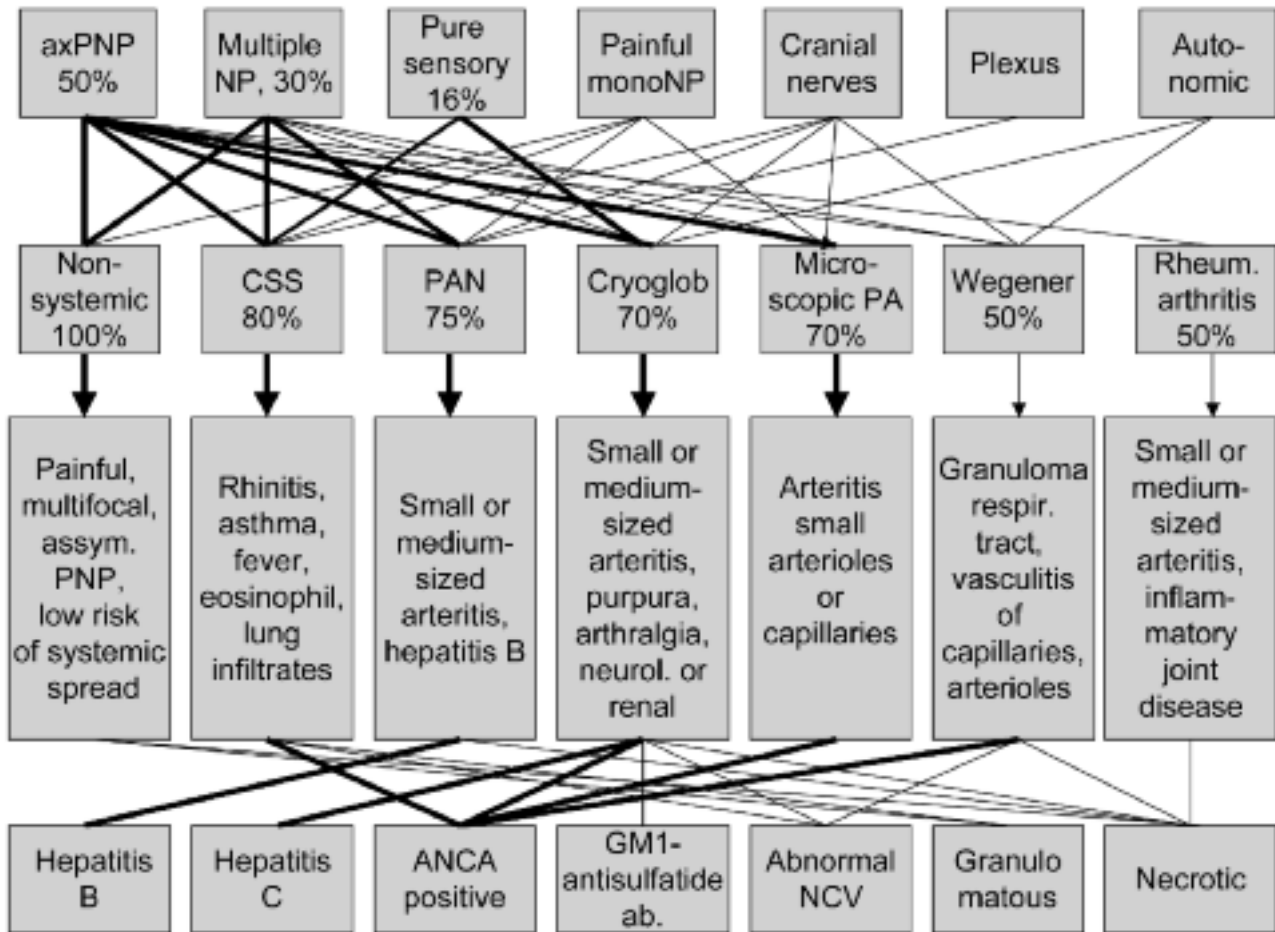


Fig. 1. — Decision tree including prevalence of PNS involvement, red flags of clinical presentation, and laboratory findings in patients with peripheral nerve involvement in the most prevalent types of primary systemic vasculitis.

vessels and less frequently the medium-sized vessels (Cacoub *et al.*, 2008, Saadoun *et al.*, 2007). Cryoglobulinemia is associated with the proliferation of B-cell clones, which produce pathogenic IgM with rheumatoid factor activity (Saadoun *et al.*, 2007). Clinical manifestations range from the mixed cryoglobulinemia syndrome (purpura, arthralgia, asthenia) to more serious manifestations with cutaneous, rheumatological (synovial), renal, or neurological manifestations (Saadoun *et al.*, 2007; Alpa *et al.*, 2008, Tada *et al.*, 2004). Neurologic manifestations predominantly affect the PNS (Saadoun *et al.*, 2007) and include painful sensorimotor PNP, pure sensory neuropathy, or mononeuritis multiplex (Schaublin *et al.*, 2005; Saadoun *et al.*, 2007). The most frequent distribution is distal sensory or sensorimotor PNP (Saadoun *et al.*, 2007). Blood chemical examination may show elevated titers of antibodies against HCV, or anti-neuronal antibodies (anti-GM1 ganglioside

or anti-sulfatide antibodies). Elevation of these antibodies is associated with evidence of active PNP (Alpa *et al.*, 2008). Traditionally, it was thought that deposits of cryoprecipitable immune complexes in the vasa nervorum cause ischemic damage of axons. The strong association between severity of PNP and the titers of GM1 and anti-sulfatide antibodies, however, suggests that these antibodies could directly trigger axonal damage (Alpa *et al.*, 2008). Symptomatic vasculitis is associated with old age, prolonged duration of infection, and high levels of type II IgM kappa cryoglobulins (Cacoub *et al.*, 2008). Mixed cryoglobulins (type I and type II) can be found in > 80% of the patients with HCV (Saadoun *et al.*, 2007; Joshi *et al.*, 2007). Between 73 and 90% of the HCV positive patients develop cryoglobulinemia (Schaublin *et al.*, 2005; Nemni *et al.*, 2003). Less frequently cryoglobulinemia is associated with lymphoma. Risk factors to develop cryoglobulinemia are

female gender, alcohol intake > 50 g/d, liver fibrosis, and steatosis hepatis (Cacoub *et al.*, 2008).

Behcet's disease

Behcet's disease is a rare multisystem vasculitis of unknown origin affecting the central nervous system in only 5% of the cases (Turker *et al.*, 2006) but the PNS in up to 20% of the cases (Akbulut *et al.*, 2007; Atasoy *et al.*, 2007). Clinically, patients with PNS involvement present with mononeuropathy, mononeuritis multiplex, sensorimotor PNP, or pure sensory PNP (Atasoy *et al.*, 2007). Sensory fibers are more dominantly affected than motor fibers (Akbulut *et al.*, 2007). PNS involvement may occur subclinically (Akbulut *et al.*, 2007). Often there is involvement of the autonomic nerves, as confirmed by delayed sympathetic skin responses (Gulturk *et al.*, 2008).

Microscopic polyangiitis

Microscopic polyangiitis is a subtype of panarteritis nodosa with the difference that it affects only small arterioles, capillaries, or venules (Schaublin *et al.*, 2005). Microscopic vasculitis is one of those subtypes most frequently associated with vasculitic neuropathy. Up to 50% of the patients with microscopic polyangiitis develop vasculitic neuropathy (Schaublin *et al.*, 2005). Microscopic polyangiitis is associated with elevated ANCA.

Schönlein-Henoch purpura

Schönlein-Henoch purpura represent a multisystem vasculitis with occasional involvement of the CNS, manifesting as headache, seizures, ataxia, or altered mental state. Only rarely the PNS is involved in form of mononeuropathies, mononeuritis multiplex, or PNP (Bulun *et al.*, 2001; Mutsukura *et al.*, 2007; Ohnuma *et al.*, 2008).

B. SECONDARY SYSTEMIC VASCULITIS

1. Connective tissue diseases

Systemic lupus erythematosus

Systemic lupus erythematosus (SLE) is an autoimmune, multi-system disorder with neurological involvement, most commonly manifesting as cerebral vasculitis, transverse myelitis, or vasculitic PNP (Ilniczky *et al.*, 2007). In a large cohort study on 670 consecutive SLE patients the prevalence of vasculitis was 11% (Ramos-Casals *et al.*, 2006). The vast majority of these patients (86%) had small vessel vasculitis and only 14% had medium-sized vasculitis (Ramos-Casals *et al.*, 2006). CNS involvement is much more frequent than PNS involvement and has been reported to occur in up to 75% of the cases

(Rafai *et al.*, 2007). PNS involvement includes classical symmetric PNP, mononeuropathies, or cranial nerve affection (Rafai *et al.*, 2007). In 37% the autonomic nervous system may be affected. Usually, anti-phospholipid antibodies are high (Rafai *et al.*, 2007). Patients with medium-sized vasculitis more frequently develop vasculitic neuropathy than patients with small-vessel vasculitis (Ramos-Casals *et al.*, 2006).

Juvenile idiopathic arthritis

Juvenile idiopathic arthritis is an inflammatory disorder of unknown etiology, affecting joints, connective tissues, viscera, and in 5% of the cases the nervous system. In the CNS juvenile idiopathic arthritis manifests as cerebral vasculitis or cervical myelopathy, in the PNS as compartment syndrome, compression neuropathy, or vasculitic neuropathy (Pineda Marfa 2002).

Rheumatoid arthritis

Though rheumatoid arthritis is predominantly an inflammatory joint disease, there are extra-articular manifestations, including neuropathy (Muramatsu *et al.*, 2008). Neuropathy in rheumatoid arthritis may not only result from entrapment or drug toxicity but also from vasculitis (Agarwal *et al.*, 2008). Rheumatoid arthritis can evolve into rheumatoid vasculitis in 2-15% of the cases and half of these patients may develop vasculitic neuropathy (Schaublin *et al.*, 2005). Vasculitis affects small to medium sized arteries, usually sparing arterioles, capillaries, or venules (Schaublin *et al.*, 2005). Many patients develop a mild sensorimotor, distal PNP or compression neuropathy distinct from vasculitic neuropathy (Schaublin *et al.*, 2005).

Sjögren syndrome

Up to 50% of the patients with Sjögren syndrome develop vasculitic neuropathy (Terrier *et al.*, 2007; Ramos-Casals *et al.*, 2008). Clinically, these patients present with acute onset mononeuritis multiplex or sensorimotor PNP. Histologically, there may be either lymphocytic or necrotizing vasculitis (Terrier *et al.*, 2007). Patients with necrotizing vasculitis appear to have a better response to immunosuppressive therapy than those with lymphocytic vasculitis (Terrier *et al.*, 2007).

Systemic sclerosis (scleroderma)

Scleroderma may be rarely associated with vasculitic neuropathy (Rosenbaum, 2001). Vasculitic neuropathy in these patients manifests as plexopathy (Allanore *et al.*, 2002) or mononeuropathy of a cranial nerve (Allanore *et al.*, 2002). In most patients the autonomic nervous system is additionally

involved (Lagana *et al.*, 1997). Single reports also described patients with mononeuritis multiplex (Nitta and Sobue, 1996).

Waldenström's macroglobulinemia

Waldenström's macroglobulinemia is a lymphoplasmocytic disorder associated with monoclonal gammopathy (Mauermann *et al.*, 2007). Most commonly patients present with a mild length-dependent sensory neuropathy, which may evolve into multiple mononeuropathies with features of systemic vasculitis (Mauermann *et al.*, 2007) and conversion of type 1 to type 2 cryoglobulinemia. Whether vasculitis in macroglobulinemia is due to the frequent association with cryoglobulinemia or hepatitis C is unknown.

2. Infections disease

Hepatitis associated vasculitis

In a single patient carrying wild-type hepatitis B virus (HBV), vasculitis of the PNS developed one week after influenza vaccination (Wada *et al.*, 2008). Clinically, he presented with mononeuritis multiplex but did not develop involvement of other organs (Wada *et al.*, 2008). Upon sural nerve biopsy predominantly small vessels were affected. The patient made a full recovery under prednisone and lamivudine. A causative role of the vaccination in the development of the vasculitis was assumed (Wada *et al.*, 2008; Takeshita *et al.*, 2006). Vasculitic neuropathy may be also found on nerve biopsy in patients with hepatitis C virus (HCV) infection without cryoglobulinemia (Nemni *et al.*, 2003).

Streptococcus infection-induced vasculitis

An abnormal auto-immune response to beta-hemolytic streptococci A causes vasculitis of the large, medium-sized, or small arteries with deposition of antigen antibody complexes within the vessel wall (Pineda Marfa 2002). Clinically, affected patients develop Sydenham's chorea (Pineda Marfa, 2002) or vasculitic neuropathy as the sole manifestation of post-infectious vasculitis (Traverso *et al.*, 1997; Mathew *et al.*, 2007).

Other infections

Rarely, vasculitic neuropathy may be induced by infections with *Bartonella henselae* (Stockmeyer *et al.*, 2007), or infection with the Epstein-Barr virus (Kanai *et al.*, 2003) or the cytomegalovirus (Schaublin *et al.*, 2005). In single cases vasculitic neuropathy may be even the first sign of an HIV infection (Mahadevan *et al.*, 2001). According to other authors neuropathy has become the most prevalent manifestation of HIV infections (de Freitas 2007). Vasculitic neuropathy in leprosy is due to affection

of the small arterioles either in form of a granulomatous vasculitis or in form of an immunocomplex type necrotic vasculitis (Nagasawa 1999).

3. Sarcoidosis

A number of studies reports on affection of the PNS in sarcoidosis (sarcoid neuropathy, sarcoid myopathy) (Said and Lacroix, 2005; Vital *et al.*, 2008). Vasculitic neuropathy in sarcoidosis presents as sensorimotor PNP, mononeuritis multiplex, painful mononeuropathies, or as CIDP (Vital *et al.*, 2008). In a retrospective study on 34 patients with sarcoidosis undergoing sural nerve biopsy, 10 (29%) showed vasculitis (Vital *et al.*, 2008). Histologically, vasculitic neuropathy in patients with sarcoidosis is of the necrotizing type (Said and Lacroix, 2005; Vital *et al.*, 2008).

4. Malignancy

Vasculitis is not infrequently associated with malignancies, such as small-cell lung carcinoma, hematologic malignancy (leukemia, myelodysplastic syndrome), lymphoma, renal cell carcinoma, or other solid tumors (Schaublin *et al.*, 2005; Fain *et al.*, 2007). Vasculitis in these patients manifests as fever, cutaneous vasculitis, arthralgias, renal insufficiency, or vasculitic neuropathy in 32% of the cases (Fain *et al.*, 2007). Involvement of the PNS is most frequently seen in patients with solid tumors (Fain *et al.*, 2007). In patients with lymphoma it may be difficult to distinguish if the associated neuropathy is due to lymphoma infiltration or vasculitis (Matsui *et al.*, 2006). Occasionally, anti-neuronal antibodies (anti-Hu, anti-Yo, anti-Ri) are elevated in paraneoplastic, vasculitic neuropathy.

5. Drugs inducing systemic vasculitis

A number of drugs has been reported to induce systemic vasculitis and potentially also vasculitic neuropathy. This is particularly the case with anti-thyroid drugs, such as propyl-thio-uracil (Frigui *et al.*, 2008). Another, similar drug is benzyl-thio-uracil, which has been reported to induce ANCA-positive vasculitis (Frigui *et al.*, 2008). Positive p-ANCA with an MPO pattern has been also reported in another patient treated with benzyl-thio-uracil (Frigui *et al.*, 2008). In a single case the non-steroidal anti-inflammatory drug naproxene induced leukocytoclastic vasculitis of the skin, vasculitic neuropathy, and nephritis (Schapira *et al.*, 2000). Other drugs, reported to cause vasculitic neuropathy include penicillin, allopurinol, cocaine, heroin, valcade, sulphonamides, or phenytoin.

Discontinuation of these drugs was beneficial in all these cases (Schapira *et al.*, 2000).

6. Radiation-induced vasculitis

Large vessel vasculitis is a rare complication of local radiation therapy (Rubin *et al.*, 2001). Only in single cases it may affect the vasculature of peripheral nerves. If the axillary artery is predominantly affected, vasculitis may manifest as brachial plexopathy (Rubin *et al.*, 2001).

7. Diabetes

A small proportion of diabetic patients develops proximal neuropathy of the lower limbs, with numbness and pain of the thighs, which worsen during the night. Symptoms progress over weeks and months to disappear spontaneously. In some patients, however, disabling weakness, amyotrophy, sensory loss, or patellar areflexia may remain (Said and Lacroix 2005). Generally, patients with lumbosacral radiculo-plexo-neuropathies due to vasculitis present with acute or subacute pain and weakness in the lower extremity with unilateral distribution at onset. In 15% of the cases also the cervicobrachial plexus is additionally affected (Schaublin *et al.*, 2005). Contrary to non-systemic vasculitic neuropathy the disease takes a monophasic course with progression lasting weeks or months but slow and incomplete recovery of motor functions (Schaublin *et al.*, 2005).

Non-systemic vasculitis

Vasculitis of exclusively the PNS is not infrequent, although less common than systemic vasculitis (Pagnoux and Guillevin 2005). This condition is also known as non-systemic vasculitis (Pagnoux and Guillevin, 2005). Patients typically present with subacute, painful, multifocal, asymmetric, distal-predominant neuropathy (Collins and Periquet 2004). Patients appear to have a high relapse rate, but low risk of systemic spread, high incidence of chronic pain, relatively good outcome, and low mortality (Collins and Periquet, 2004). After a static period, a slow gradual return of function typically occurs for a given nerve (Schaublin *et al.*, 2005). The outcome is better than with systemic vasculitis and mortality in the majority of the studies low (Collins and Periquet 2004). In a series of 29 patients, however, 37% died after an average of 3.3y after neuropathy onset (Said and Lacroix 2005). In a single patient isolated vasculitis of the sural nerve has been reported (Stickler *et al.*, 2006). Also in a single patient vasculitis neuropathy was associated with elevated anti-cardi-

olipin antibodies (Jeruc *et al.*, 2006). Clinically, this patient presented with mononeuritis multiplex and had a history of seven spontaneous abortions, Raynaud phenomenon, and livedo reticularis (Jeruc *et al.*, 2006). Sural nerve biopsy revealed necrotizing vasculitis of the epineural arteries with transmural infiltrates and thrombosis (Jeruc *et al.*, 2006). In 6-37% of the cases presumed non-systemic vasculitis actually turns into a systemic vasculitis, which initially exclusively presents with neuropathy (Schaublin *et al.*, 2005, Collins and Periquet 2004, Said and Lacroix 2005). Some authors even doubt that a vasculitis exclusively of the PNS exists and prefer to talk about a systemic low-grade vasculitis, which becomes symptomatic only in the PNS (Said and Lacroix, 2005).

Differential diagnoses

The most frequent differentials of vasculitic neuropathy include axonal polyneuropathy of other origin, including borreliosis, Guillain-Barre syndrome (GBS), CIDP, or chronic idiopathic axonal PNP (Vrancken *et al.*, 2004). Rarely, the PNS of patients with T-cell lymphoma may be affected, manifesting as cranial nerve palsies or mononeuritis multiplex (Levin *et al.*, 2008). Affection of the PNS in such patients may be either due to neurolymphomatosis or due to vasculitis (Levin *et al.*, 2008). Infiltration of the PNS by the lymphoma is more frequent than by vasculitis (Levin *et al.*, 2008). Nerve biopsy may help to differentiate between neurolymphomatosis and vasculitis in these patients.

Diagnostic work-up

1. History, examination, blood chemical investigations

History, clinical examination and a routine blood chemical investigation are the basis of the diagnostic work-up for vasculitic neuropathy. Additionally, an electrophoresis, determination of immunoglobulins, complement factors, rheuma factors, anti-nuclear antibodies (ANA), p-ANCA, c-ANCA, MPO-ANCA, and circulating immune-complexes should be carried out. Laboratory tests frequently indicate features of systemic inflammation, such as elevated sedimentation rate, increased C-reactive protein, or positive ANCA (Gorson 2007). ANCA are usually elevated in small vessel vasculitis (Table 1) and necrotizing vasculitis (CSS, Wegener, PAN, Schoenlein Henoch purpura, Kawasaki syndrome), but may be also found in single cases with giant cell arteritis. Pathogenomic for LES are anti-La/SS-BL antibodies

(Ramos-Casals *et al.*, 2006). Basic essential investigations also comprise a X-ray of the lung to screen for sarcoidosis, eosinophilic infiltration, or lymphoma. If sarcoidosis is suspected a CT of the lung or bronchoscopy is mandatory, as well as the determination of the angiotensin-converting enzyme (Bonfioli and Orefice 2005). VDRL and TPHA should be determined to exclude a luetic infection (Mathew *et al.*, 2007). Determination of antibodies against HBV or HCV are essential to exclude hepatitis-associated vasculitis (Wada *et al.*, 2008). The HIV-status needs to be determined. Cryoglobulins I and II need to be determined from a serum, which has been kept at 37°C to avoid premature precipitation (Schaublin *et al.*, 2005).

2. Electrophysiological investigations

Nerve conduction studies are essential to raise the suspicion of a vasculitic neuropathy, vasculitic plexopathy, or in selecting the nerve for biopsy (Lacomis and Zivkovic 2007; Sanchez *et al.*, 2001). Not only nerves clinically affected should undergo nerve conduction studies, but also nerves which appear clinically unaffected but may be subclinically involved. Though most frequently motor and sensory fibers are involved, also the autonomic nervous system should be tested. Though the distal portions of motor and sensory fibers are predominantly affected in the majority of the cases, also the proximal parts may be occasionally involved (diabetes), requiring proximal nerve conduction studies. Needle electromyography can be useful to confirm the neurogenic nature of the lesion, particularly in cases with co-pathologies.

3. Nerve biopsy

The golden standard of diagnosing vasculitic PNP is nerve biopsy (Zivkovic *et al.*, 2007). In the vast majority of the cases the sural nerve is biopsied but sensory fibers of the superficial peroneal nerve (N. cutaneous dorsalis) can be also taken (Hilton *et al.*, 2007), although the area of sensory loss may be larger as compared to sural nerve biopsy (Hilton *et al.*, 2007). The sensitivity of nerve biopsy is at most 60% (Oka *et al.*, 2007). It is dependent on the selection of patients, which nerve was selected, timing in relation to symptoms, and the histological criteria applied for diagnosis (Schaublin *et al.*, 2005). A useful target to demonstrate vasculitis on biopsy may be co-expression of the antigens N-epsilon-carboxymethyl-lysine, the receptor for advanced glycation end products (RAGE), or NF-kappaBp65 (Haslbeck *et al.*, 2007). To increase the low sensitivity of nerve biopsy some authors propose to obtain also muscle

specimens together with nerve biopsy (Said and Lacroix 2005). The low sensitivity may be also due to the segmental character of nerve vasculitis, why it is proposed to study serial sections of the affected nerve (Said and Lacroix 2005).

Histological findings on nerve biopsy

Histopathologic findings in PNS vasculitis include vasculitis of the large (> 100 µm) nerve arterioles, small (40-100 µm) nerve arterioles (microvasculitis), of capillaries, or the venules (Burns *et al.*, 2007; Vital *et al.*, 2008). Particularly, large or medium nerve arterioles are affected in patients with Wegener's granulomatosis, PAN, rheumatoid arthritis, or SLE (Vincent *et al.*, 2007; Ohkoshi *et al.*, 1996). Small arterioles are particularly affected in microscopic polyangiitis or mixed cryoglobulinemia (Table 1) (Schaublin *et al.*, 2005). Vasculitis may appear either as lymphocytic/monocytic infiltration or necrotizing degeneration (Terrier *et al.*, 2007). Necrotizing vasculitis occurs in cryoglobulinemia (Tada *et al.*, 2004; Vincent *et al.*, 2007) or Sjögren syndrome (Terrier *et al.*, 2007). Necrotizing vasculitis may be also observed in patients with non-systemic vasculitis and elevated anti-cardiolipin antibodies (Jeruc *et al.*, 2006). Necrotizing vasculitis, predominantly involving the small vessels, and manifesting as mononeuritis multiplex may also develop after influenza vaccination (Wada *et al.*, 2008). Necrotizing vasculitis is also a feature in patients with sarcoidosis (Vital *et al.*, 2008), PAN (Harada *et al.*, 2000; Said 1997), rheumatoid arthritis, SLE, or Wegener's granulomatosis (Said and Lacroix, 2005). In cases of sarcoidosis and non-systemic vasculitis granulomatous vasculitis can be found (Vital *et al.*, 2008). HBs-antigen can be observed in a high density around the vessels of the epineurium in the sural nerve (Wada *et al.*, 2008). Infiltrates in CSS vasculitis are mainly composed of CD8 positive suppressor and CD4 positive helper T-lymphocytes (Hattori *et al.*, 1999).

Therapy

Treatment decisions should be made in consultation with rheumatologists, infectiologists, hematologists, and oncologists and are dependent on the type of vasculitis, extent and progression of organ involvement, prior responsiveness to any treatment, and presence or absence of a viral infection (Schaublin *et al.*, 2005).

Non-viral vasculitis

For non-viral, systemic vasculitis the application of corticosteroids (1-2 mg/kg/d oral prednisone in mild cases or 1000 mg intravenous methylprednisolone for 5 days followed by daily oral

prednisone during 6-8 weeks in severe cases) is the first line measure (Pagnoux and Guillevin 2005). If corticosteroids are ineffective or if vasculitis relapses upon tapering of steroids, immunosuppression with cyclophosphamide or other immunosuppressive drugs is recommended (Table 4) (Garson, 2007; Djukic *et al.*, 2008). Cyclophosphamide may be applied as intravenous pulses or daily application together with steroids for 3 to 12 months (Garson, 2007; Gorson, 2006). Immunosuppressive therapy can be also applied without additional medication or in addition to corticosteroids, like in CSS associated vasculitis (Zwerina *et al.*, 2008). In patients who do not tolerate cyclophosphamide or have contra-indications, azathioprine, methotrexate, mycophenolate mofetil, or rituximab can be tried (Table 4) (Garson, 2007). Rituximab, administered weekly for 2 weeks in three cases and 4 weeks in six patients, stabilized neuropathy in only one of them. On the contrary, rituximab may be particularly effective in ANCA-positive vasculitis (Eriksson, 2005). Cyclophosphamide can be safely substituted after three or four

months by azathioprine or methotrexate without increasing the relapse rate (Schaublin *et al.*, 2005; Gorson, 2006). If steroids and cyclophosphamide are ineffective in CSS, interferon-alpha is an alternative option. Disadvantage of immunosuppression other than cyclophosphamide, however, is that the experience with these agents is limited to single cases or small case series (Garson, 2007; Benamour *et al.*, 2006). No randomized controlled trials have been carried out which assessed the efficacy of a specific treatment (Vrancken *et al.*, 2007).

Additional therapeutic options are immunoadsorption or plasma exchange, which can be effective to eliminate Ro-antibodies but do not seem to improve survival in severe cases (Garson, 2007; Schaublin *et al.*, 2005; Harscher *et al.*, 2007). A further alternative to immunosuppression is the application of immunoglobulins (Garson, 2007). Immunoglobulins may be particularly effective in patients with Sjögren syndrome, SLE, vaccination-induced vasculitis, CSS, PAN, or scleroderma, resistant to immunosuppressive drugs (Levy *et al.*,

Table 4

Therapy of vasculitic neuropathy (Schaublin *et al.* 2005)

Non-viral vasculitis	
Steroids	
	1-2 mg/kg/d prednisone (mild cases) or 1 g/d methyl-prednisolone iv for 5 d (severe cases) followed by 1-2 mg/kg/d prednisone until effect (6-8 w), afterwards every second day (same dosage or half dosage)
Cyclophosphamide	
	If steroids are ineffective or multi-system involvement either 2 mg/kg during 3-12 m or pulse therapy intravenously with 500 mg/m ² once every 4-6 w during 1a
Methotrexate	
	Indicated if cyclophosphamide is ineffective or as long-term therapy after remission under steroids plus cyclophosphamide, start with 0.3 mg/kg (maximally 15 mg) once a week and increase to 15-25 mg/week thereafter
Azathioprine	
	Indicated if cyclophosphamide is ineffective or as long-term therapy after remission under steroids plus cyclophosphamide, at the beginning 1 mg/kg/d later on 2-2.5 mg/kg/d
Mycophenolate mofetil	
	Only pilot studies available, possibly effective in Wegener's granulomatosis
Leflunomide	
	Only pilot studies available, possibly effective in Wegener's granulomatosis
Rituximab	
	Only pilot studies available, particularly effective in ANCA-positive vasculitis
Immunoglobulines	
	Open-label studies suggest clinical benefit and reduction of inflammatory markers
Virus-induced vasculitis	
Steroids	
	Prednisone (1 mg/kg/d) during 1 week followed by a taper during the second week
Interferon	
	IFa-2b or lamivudine during 6m after steroids for hepatitis B-associated vasculitis, in case of hepatitis C, pegylated IFa-2a or IFa-2b, ribavirin (400-600 mg/2x/d) should be added for 1a
Rituximab	
	In pilot open label studies effective in hepatitis C-associated cryoglobulinemia
Plasma exchange	
	May be considered in fulminate cases of cryoglobulinemia

2005). Immunoglobulins are contra-indicated in viral-associated systemic vasculitis (Schaublin *et al.*, 2005).

Virus-induced vasculitis

Therapy in patients with hepatitis B-associated vasculitis should start with steroids during 2 weeks, followed by the application of interferon alpha-2b or lamivudine during 6 months (Schaublin *et al.*, 2005; Wada *et al.*, 2008; Takeshita *et al.*, 2006). In patients with hepatitis C-associated vasculitis therapy starts with pegylated interferon alpha-2a or 2b. Ribavirin can be added during 1 year (Table 4). In patients with vasculitic PNP associated with cryoglobulinemia antiviral therapy with interferon, pegylated interferon, interferon plus ribavirin, or pegylated interferon plus ribavirin may be beneficial in about 80% of the cases (Cacoub *et al.*, 2008; Joshi *et al.*, 2007). Pegylated interferon alpha plus ribavirin are effective in approximately 70% of the cases, but the effectiveness of rituximab is slightly higher (Cacoub *et al.*, 2008).

Prognosis

Approximately 15% of the patients with vasculitic PNP develop malignancy within two years after onset of PNP (Zivkovic *et al.*, 2007). This is particularly the case in patients with Sjögren syndrome or HCV infection, who develop lymphoma more frequently than patients with other causes of vasculitic neuropathy (Ramos-Casals *et al.*, 2006). Despite clinical improvement upon long-term immunotherapy, the overall prognosis of patients with vasculitic neuropathy due to systemic vasculitis remains poor and is often fatal (Schaublin *et al.*, 2005; Fouget, 2000). Though patients with non-systemic vasculitis appear to have a high relapse rate, they have a low risk of systemic spread and low mortality (Collins and Periquet, 2004). The outcome in these patients is better than with systemic vasculitis and better on combination therapy than corticosteroids alone (Collins and Periquet 2004).

Conclusions

Vasculitic neuropathy is an important differential of PNS neuropathy. Vasculitic neuropathy should be considered if there are subacute, axonal, asymmetric sensorimotor, PNP, painful mononeuropathies, including the cranial nerves, pure sensory PNP, or autonomic PNP alone or in association with systemic manifestations of vasculitis, such as headache, cognitive impairment, psychosis, disorientation, hallucinations, stroke, or seizures (CNS involvement) (Harscher *et al.*, 2007), asthma, hemoptysis, alveolar

hemorrhaghe (pulmonary involvement), nephritis, renal failure (renal involvement), hemorrhagic skin lesions, livedo reticularis (skin involvement), or polyarthritides (joint involvement). For diagnosing the condition nerve biopsy is warranted, although in patients with systemic vasculitis and evidence of vasculitis in organs other than the peripheral nerves, nerve biopsy is not indicated. In case of non-viral vasculitic neuropathy therapy should start with steroids and cyclophosphamide. If ineffective, it should be replaced by other immunosuppressive agents. Secondary systemic vasculitis additionally requires treatment of the disorder underlying the vasculitis. The prognosis may be favorable in non-systemic vasculitis but can be fatal in systemic vasculitis.

REFERENCES

- Agarwal V, Singh R, Wiclaf, Chauhan S *et al.* A clinical, electrophysiological, and pathological study of neuropathy in rheumatoid arthritis. *Clin Rheumatol.* 2008;27:841-844.
- Akbulut L, Gur G, Bodur H, Alli N, Borman P. Peripheral neuropathy in Behçet disease: an electroneurophysiological study. *Clin Rheumatol.* 2007;26:1240-1244.
- Allanore Y, Zuber M, Kahan A. Brachial plexopathy associated with systemic sclerosis. *Clin Rheumatol.* 2002;21:401-402.
- Allen RK, Sellars RE, Sandstrom PA. A prospective study of 32 patients with neurosarcoidosis. *Sarcoidosis Vasc Diffuse Lung Dis.* 2003;20:118-125.
- Alpa M, Ferrero B, Cavallo R, Naretto C, Menegatti E. *et al.* Anti-neuronal antibodies in patients with HCV-related mixed cryoglobulinemia. *Autoimmun Rev.* 2008;(in press).
- Atasoy HT, Tunc TO, Unal AE, Emre U, Koca R. *et al.* Peripheral nervous system involvement in patients with Behçet disease. *Neurologist.* 2007;13:225-230.
- Benamour S, Naji T, Alaoui FZ, El-Kabli H, El-Aidouni S. Neurological involvement in Behçet's disease. 154 cases from a cohort of 925 patients and review of the literature. *Rev Neurol (Paris).* 2006;162:1084-1090.
- Bonfioli AA, Orefice F. Sarcoidosis. *Semin Ophthalmol.* 2005;20:177-182.
- Bulun A, Topaloglu R, Duzova A, Saatci I, Besbas N. *et al.* Ataxia and peripheral neuropathy: rare manifestations in Henoch-Schönlein purpura. *Pediatr Nephrol.* 2001;16:1139-1141.
- Burns TM, Schaublin GA, Dyck PJ. Vasculitic neuropathies. *Neurol Clin.* 2007;25:89-113.
- Cacoub P, Delluc A, Saadoun D, Landau DA, Sene D. Anti-CD20 monoclonal antibody (rituximab) treatment for cryoglobulinemic vasculitis: where do we stand? *Ann Rheum Dis.* 2008;67:283-287.

- Cattaneo L, Chierici E, Pavone L, Grasselli C, Manganelli P. *et al.* Peripheral neuropathy in Wegener's granulomatosis, Churg-Strauss syndrome and microscopic polyangiitis. *J Neurol Neurosurg Psychiatry.* 2007;78:1119-1123.
- Chao CC, Hsieh ST, Shun CT, Hsieh SC. Skin denervation and cutaneous vasculitis in eosinophilia-associated neuropathy. *Arch Neurol.* 2007;64:959-965.
- Collins MP, Periquet MI. Non-systemic vasculitic neuropathy. *Curr Opin Neurol.* 2004;17:587-598.
- Coppeto JR, Adamczyk D. Anterior ischemic optic neuropathy in Buerger's disease. *Ann Ophthalmol.* 1988;20:332-334.
- Dickey W, Andrews WJ. Wegener's granulomatosis presenting as peripheral neuropathy: diagnosis confirmed by serum anti-neutrophil antibodies. *J Neurol Neurosurg Psychiatry.* 1990;53:269-270.
- Djukic M, Schmidt H, Mazurek C, König F, Schweyer S. *et al.* A patient with Churg-Strauss syndrome presenting as Guillain-Barré syndrome. *Nervenarzt.* 2008;79:457-461.
- Eriksson P. Nine patients with anti-neutrophil cytoplasmic antibody-positive vasculitis successfully treated with rituximab. *J Intern Med.* 2005;257:540-548.
- Fain O, Hamidou M, Cacoub P, Godeau B, Wechsler B. *et al.* Vasculitides associated with malignancies: analysis of sixty patients. *Arthritis Rheum.* 2007;57:1473-1480.
- Feuerlein S, Brambs HJ, Pauls S. PTFE implant of the plica vocalis: pitfall in Wegener granulomatosis in contrast enhanced computer tomography. *Rofo.* 2008;180:350-351.
- de Freitas MR. Infectious neuropathy. *Curr Opin Neurol.* 2007;20:548-552.
- Frigui M, Kechaou M, Haddouk S, Masmoudi A, Kaddour N. *et al.* Benzylthiouracil induced ANCA-positive vasculitis: study of three cases and review of the literature. *Ann Endocrinol (Paris).* 2008;(in press).
- Gorson KC. Vasculitic neuropathies: an update. *Neurologist.* 2007;13:12-19.
- Gorson KC. Therapy for vasculitic neuropathies. *Curr Treat Options Neurol.* 2006;8:105-117.
- Gulturk S, Akyol M, Kececi H, Ozcelik S, Cinar Z, Demirkazik A. Delayed habituation in Behcet's disease. *Neurol India.* 2008;56:27-30.
- Hagiwara N, Sekijima Y, Hattori T, Hashimoto T, Ikeda S. Two patients with different types of vasculitic neuropathy - a comparison between cutaneous polyarteritis nodosa and nonsystemic vasculitic neuropathy. *Rinsho Shinkeigaku.* 2003;43:102-108.
- Harada K, Hirayama K, Hori M, Ohkoshi N. Sensory ataxic dominant neuropathy associated with polyarteritis nodosa. *Intern Med.* 2000;39:847-851.
- Harscher S, Rummeler S, Oelzner P, Mentzel HJ, Brodhun M. *et al.* Selective immunoadsorption in neurologic complications of systemic lupus erythematosus. *Nervenarzt.* 2007;78:441-444.
- Haslbeck KM, Neundörfer B, Schlötzer-Schrehardt U, Bierhaus A, Schleicher E. *et al.* Activation of the RAGE pathway: a general mechanism in the pathogenesis of polyneuropathies? *Neurol Res.* 2007;29:103-110.
- Hattori N, Ichimura M, Nagamatsu M, Li M, Yamamoto K. *et al.* Clinicopathological features of Churg-Strauss syndrome-associated neuropathy. *Brain.* 1999;122:427-439.
- Hello C, Mouthon L, Larroche C, Lemaire V, Piette AM. *et al.* Vasculitides associated with malignancies: analysis of sixty patients. *Arthritis Rheum.* 2007;57:1473-1480.
- Hicks JT, Korenyi-Both A, Utsinger PD, Baran EM, McLaughlin GE. Neuromuscular and immunohistochemical abnormalities in an adult man with Kawasaki disease. *Ann Intern Med.* 1982;96:607-610.
- Hilton DA, Jacob J, Househam L, Tengah C. Complications following sural and peroneal nerve biopsies. *J Neurol Neurosurg Psychiatry.* 2007;78:1271-1272.
- Ilniczky S, Kamondi A, Arányi Z, Várallyay G, Gaal B. *et al.* Simultaneous central and peripheral nervous system involvement in systemic lupus erythematosus. *Ideggyogy Sz.* 2007;60:398-402.
- Lopate G, Pestronk A, Al-Lozi M, Lynch T, Florence J. *et al.* Peripheral neuropathy in an outpatient cohort of patients with Sjögren's syndrome. *Muscle Nerve.* 2006;33:672-676.
- Jeruc J, Popovic M, Vizjak A, Jurčić V, Lestan B. *et al.* Multiple mononeuropathy due to vasculitis associated with anticardiolipin antibodies: a case report. *Folia Neuropathol.* 2006;44:140-143.
- Jimenez-Medina HJ, Yablon SA. Electrodiagnostic characteristics of Wegener's granulomatosis-associated peripheral neuropathy. *Am J Phys Med Rehabil.* 1992;71:6-11.
- Joshi S, Kuczynski M, Heathcote EJ. Symptomatic and virological response to antiviral therapy in hepatitis C associated with extrahepatic complications of cryoglobulinemia. *Dig Dis Sci.* 2007;52:2410-2417.
- Kanai K, Kuwabara S, Mori M, Arai K, Yamamoto T. *et al.* Leukocytoclastic-vasculitic neuropathy associated with chronic Epstein-Barr virus infection. *Muscle Nerve.* 2003;27:113-116.
- Kostina-O'Neil Y, Jirawuthiworavong GV, Podell DN, Lesser RL. Choroidal and optic nerve infarction in hepatitis C-associated polyarteritis nodosa. *J Neuroophthalmol.* 2007;27:184-188.
- Lacomis D, Zivković SA. Approach to vasculitic neuropathies. *J Clin Neuromuscul Dis.* 2007;9:265-276.
- Laganà B, Gentile R, Vella C, Giovani A, Tubani L. *et al.* Heart and autonomic nervous system in connective tissue disorders. *Recenti Prog Med.* 1997;88:579-584.
- Levin N, Soffer D, Grissaru S, Aizikovitch N, Gomori JM. *et al.* Primary T-cell CNS lymphoma presenting with leptomeningeal spread and neurolymphomatosis. *J Neurooncol.* 2008;90:77-83.

- Levy Y, Uziel Y, Zandman G, Rotman P, Amital H. *et al.* Response of vasculitic peripheral neuropathy to intravenous immunoglobulin. *Ann N Y Acad Sci.* 2005;1051:779-786.
- Mahadevan A, Gayathri N, Taly AB, Santosh V, Yasha TC. *et al.* Vasculitic neuropathy in HIV infection: a clinicopathological study. *Neurol India.* 2001;49:277-283.
- Marsot-Dupuch K, De Givry SC, Ouayoun M. Wegener granulomatosis involving the pterygopalatine fossa: an unusual case of trigeminal neuropathy. *AJNR Am J Neuroradiol.* 2002;23:312-315.
- Mathew L, Talbot K, Love S, Puvanarajah S, Donaghy M. Treatment of vasculitic peripheral neuropathy: a retrospective analysis of outcome. *QJM.* 2007;100:41-51.
- Matsui H, Udaka F, Kubori T, Oda M, Nishinaka K, Oka N. HTLV-I-associated peripheral neuropathy with smoldering-type adult T-cell leukemia. *Neurologist.* 2006;12:109-113.
- Mauermann ML, Ryan ML, Moon JS, Klein CJ. Case of mononeuritis multiplex onset with rituximab therapy for Waldenström's macroglobulinemia. *J Neurol Sci.* 2007;260:240-243.
- Muramatsu K, Tanaka H, Taguchi T. Peripheral neuropathies of the forearm and hand in rheumatoid arthritis: diagnosis and options for treatment. *Rheumatol Int.* 2008;28:951-957.
- Mutsukura K, Tsuboi Y, Fujiki F, Fujioka S, Inoue H. *et al.* Acute motor sensory axonal neuropathy associated with Henoch-Schönlein purpura. *J Neurol Sci.* 2007;263:169-173.
- Nagasawa T. Leprous neuropathy - observation from the standpoint vasculitis. *Nihon Hansenbyo Gakkai Zasshi.* 1999;68:67-70.
- Nemni R, Sanvito L, Quattrini A, Santuccio G, Camerlingo M. *et al.* Peripheral neuropathy in hepatitis C virus infection with and without cryoglobulinaemia. *J Neurol Neurosurg Psychiatry.* 2003;74:1267-1271.
- Nitta Y, Sobue G. Progressive systemic sclerosis associated with multiple mononeuropathy. *Dermatology.* 1996;193:22-26.
- Ohkoshi N, Mizusawa H, Oguni E, Shoji S. Sural nerve biopsy in vasculitic neuropathies: morphometric analysis of the caliber of involved vessels. *J Med.* 1996;27:153-170.
- Ohnuma K, Hosono O, Kawasaki H, Yoshikawa N, Katayose T. *et al.* An adult case of Henoch-Schönlein purpura complicating common peroneal nerve mononeuropathy. *Mod Rheumatol.* 2008;(in press).
- Oka N, Kawasaki T, Mizutani K, Sugiyama H, Akiguchi I. Hypoxia-inducible factor 1alpha may be a marker for vasculitic neuropathy. *Neuropathology.* 2007;27:509-515.
- Pagnoux C, Guillevin L. Peripheral neuropathy in systemic vasculitides. *Curr Opin Rheumatol.* 2005;17:41-48.
- Perry JD, Girkin CA, Miller NR, Mann RB. Disseminated histoplasmosis causing reversible gaze palsy and optic neuropathy. *J Neuroophthalmol.* 1999;19:140-143.
- Pfadenhauer K, Roesler A, Golling A. The involvement of the peripheral nervous system in biopsy proven active giant cell arteritis. *J Neurol.* 2007;254:751-755.
- Pineda Marfa M. Neurological involvement in rheumatic disorders and vasculitis in childhood. *Rev Neurol.* 2002;35:290-296.
- Pineles SL, Arnold AC. Giant cell arteritis. *Int Ophthalmol Clin.* 2007;47:105-119.
- Pleasure D. Peripheral neuropathy as the first clinical manifestation of Wegener granulomatosis. *Arch Neurol.* 2001;58:1204.
- Pouget J. Vascular neuropathies. *Rev Prat.* 2000;50:749-752.
- Rafai MA, Fadel H, Boulaajaj FZ, Gam I, El Moutawakkil B. *et al.* Peripheral neuropathy in systemic lupus erythematosus with epineural vasculitis and antiphospholipid antibodies. *Rev Neurol (Paris).* 2007;163:103-106.
- Ramos-Casals M, Solans R, Rosas J, Camps MT, Gil A. *et al.* GEMESS Study Group. Primary Sjögren syndrome in Spain: clinical and immunologic expression in 1010 patients. *Medicine (Baltimore).* 2008;87:210-219.
- Ramos-Casals M, Nardi N, Lagrutta M, Brito-Zerón P, Bové A. *et al.* Vasculitis in systemic lupus erythematosus: prevalence and clinical characteristics in 670 patients. *Medicine (Baltimore).* 2006;85:95-104.
- Rosenbaum R. Neuromuscular complications of connective tissue diseases. *Muscle Nerve.* 2001;24:154-169.
- Rubin DI, Schomberg PJ, Shepherd RF, Panneton JM. Arteritis and brachial plexus neuropathy as delayed complications of radiation therapy. *Mayo Clin Proc.* 2001;76:849-852.
- Saadoun D, Bieche I, Authier FJ, Laurendeau I, Jambou F. *et al.* Role of matrix metalloproteinases, pro-inflammatory cytokines, and oxidative stress-derived molecules in hepatitis C virus-associated mixed cryoglobulinemia vasculitis neuropathy. *Arthritis Rheum.* 2007;56:1315-1324.
- Said G, Lacroix C. Primary and secondary vasculitic neuropathy. *J Neurol.* 2005;252:633-641.
- Said G, Lacroix C, Lozeron P, Ropert A, Planté V, Adams D. Inflammatory vasculopathy in multifocal diabetic neuropathy. *Brain.* 2003;126:376-385.
- Said G. Necrotizing peripheral nerve vasculitis. *Neurol Clin.* 1997;15:835-848.
- Sánchez J, Coll-Cantí J, Ariza A, Olivé A, Cuixart A. *et al.* Neuropathy due to necrotizing vasculitis: a study of the clinical anatomy, neurophysiological characteristics, and clinical course of the disorder in 27 patients. *Rev Neurol.* 2001;33:1033-1036.
- Schapira D, Balbir-Gurman A, Nahir AM. Naproxen-induced leukocytoclastic vasculitis. *Clin Rheumatol.* 2000;19:242-244.

- Schaublin GA, Michet CJ Jr, Dyck PJ, Burns TM. An update on the classification and treatment of vasculitic neuropathy. *Lancet Neurol*. 2005;4:853-865.
- Seo JH, Ryan HF, Claussen GC, Thomas TD, Oh SJ. Sensory neuropathy in vasculitis: a clinical, pathologic, and electrophysiologic study. *Neurology*. 2004;63:874-878.
- Servioli L, Pérez C, Consani S, Suárez A, Sehabiaga G. *et al*. Prevalence and characteristics of immunomediated neuropathies in a group of patients with autoimmune diseases. *J Clin Neuromuscul Dis*. 2007; 9:285-290.
- Shoshtry J, Adib M. Peripheral neuropathy in systemic lupus erythematosus in Southern Iran. *Electromyogr Clin Neurophysiol*. 2005;45:145-148.
- Stickler DE, Morley KN, Massey EW. Sural neuropathy: etiologies and predisposing factors. *Muscle Nerve*. 2006;34:482-484.
- Stockmeyer B, Schoerner C, Frangou P, Moriabadi T, Heuss D. *et al*. Chronic vasculitis and polyneuropathy due to infection with *Bartonella henselae*. *Infection*. 2007;35:107-109.
- Tada M, Naruse S, Arai A, Sato A, Tanaka K. *et al*. An autopsy case of systemic vasculitis associated with hepatitis C virus-related mixed cryoglobulinemia presenting severe peripheral neuropathy. *Rinsho Shinkeigaku*. 2004;44:686-690.
- Takeshita S, Nakamura H, Kawakami A, Fukushima T, Gotoh T. *et al*. Hepatitis B-related polyarteritis nodosa presenting necrotizing vasculitis in the hepatobiliary system successfully treated with lamivudine, plasmapheresis and glucocorticoid. *Intern Med*. 2006;45:145-149.
- Tanaka H, Yuki N, Ohnishi A, Hirata K. A case of polyneuropathy by microscopic polyarteritis nodosa. *No To Shinkei*. 1998;50:1107-1111.
- Terrier B, Lacroix C, Guillevin L, Hatron PY, Dhote R. *et al*. Club Rhumatismes et Inflammation. Diagnostic and prognostic relevance of neuromuscular biopsy in primary Sjögren's syndrome-related neuropathy. *Arthritis Rheum*. 2007;57:1520-1529.
- Traverso F, Martini F, Banchi L, Maritato F, Fazio B. Vasculitic neuropathy associated with beta-haemolytic streptococcal infection: a case report. *Ital J Neurol Sci*. 1997;18:105-107.
- Turker H, Cengiz N, Akar H, Onar MK, Us O. Effects of high stimulus frequencies on SEPs of patients with neuro-Behcet's Disease. *Can J Neurol Sci*. 2006; 33:387-393.
- Vincent D, Gombert B, Vital A, Vital C. A case of mononeuropathy multiplex with type II cryoglobulinemia, necrotizing vasculitis and low grade B cell lymphoma. *Clin Neuropathol*. 2007;26: 28-31.
- Vincent D, Dubas F, Hauw JJ, Escourolle R, Godeau P. *et al*. Nerve and muscle microvasculitis: 50 cases. *Rev Neurol (Paris)*. 1985;141:440-446.
- Vital A, Lagueny A, Ferrer X, Louiset P, Canron MH. *et al*. Sarcoid neuropathy: clinico-pathological study of 4 new cases and review of the literature. *Clin Neuropathol*. 2008;27:96-105.
- Vrancken AF, Hughes RA, Said G, Wokke JH, Notermans NC. Immunosuppressive treatment for non-systemic vasculitic neuropathy. *Cochrane Database Syst Rev*. 2007;(1):CD006050.
- Vrancken AF, Notermans NC, Jansen GH, Wokke JH, Said G. Progressive idiopathic axonal neuropathy - a comparative clinical and histopathological study with vasculitic neuropathy. *J Neurol*. 2004;251: 269-278.
- Wada Y, Yanagihara C, Nishimura Y, Oka N. Hepatitis B virus-related vasculitis manifesting as severe peripheral neuropathy following influenza vaccination. *Clin Neurol Neurosurg*. 2008;110:750-752.
- Wood LE, Tulloh RM. Kawasaki Disease in Children. *Heart*. 2008;(in press).
- Yamamoto M, Ito Y, Mitsuma N, Hattori N, Sobue G. Pain-related differential expression of NGF, GDNF, IL-6, and their receptors in human vasculitic neuropathies. *Intern Med*. 2003;42:1100-1103.
- Zivković SA, Ascherman D, Lacomis D. Vasculitic neuropathy – electrodiagnostic findings and association with malignancies. *Acta Neurol Scand*. 2007;115: 432-436.
- Zwerina J, Eger G, Englbrecht M, Manger B, Schett G. Churg-Strauss Syndrome in Childhood: A Systematic Literature Review and Clinical Comparison with Adult Patients. *Semin Arthritis Rheum*. 2008;(in press).

Univ. Prof. Dr. J. Finsterer, M.D., Ph.D.,
Schindlergasse 9/10,
1180 Vienna (Austria).
E-mail: fipaps@yahoo.de