



An extreme lateral lumbar disc herniation mimicking L4 schwannoma

B. BAKAR¹, M. M. SUMER², A. CILA³ and I. H. TEKKOK¹

¹Department of Neurosurgery, ²Department of Neurology, MESA Hospital, Yasam Caddesi No: 5 Sogutozu, 06510 Ankara, Turkey;

³Department of Radiology, MESA Hospital, Yasam Caddesi No: 5 Sogutozu, 06510 Ankara, Turkey and Hacettepe University, School of Medicine, Department of Radiology, Sıhhiye 06100, Ankara, Turkey

Abstract

Objective: We herein describe a case with an extraspinal mass distorting the right L4 dorsal root ganglion. Initially presumed to be a nerve root schwannoma, the lesion turned out to be a free disc fragment.

Methods and Results: A 46-year-old woman presented with a history of mild low back and intense right leg pain. The leg pain was like electrical discharges. Right knee extension was weak together with hyperalgesia and loss of heat sensation in the right L4 dermatome. The right patellar reflex was absent. Electromyography showed acute and chronic denervation of muscles innervated by the right L4 nerve root. MR scan showed a right L4-5 extraforaminal mass distorting the L4 dorsal root ganglion. The mass enhanced homogeneously after gadolinium injection and was thought to be a tumor. It was surgically removed using a midline incision and intraspinal, followed by extraspinal dissection. Under the operating microscope, the mass extended between an intact lateral longitudinal ligament and a swollen dorsal root ganglion. Histopathologic examination ruled out a tumor and showed that the mass consisted of degenerated disc material surrounded by a large peripheral zone of neovascularization.

Conclusion: Extraforaminal periganglionic free, encapsulated disc fragments may mimic tumoral masses, from which they may not be distinguished on MRI.

Key words: Lumbar disc; herniation; schwannoma; MRI.

Introduction

Extraforaminal disc herniations are far more less common than intraspinal and foraminal disc herniations (Grenier *et al.*, 1990). Rare neoplastic masses (such as schwannomas) can also occur in this region and such neoplastic lesions are often misdiagnosed as intervertebral disc disease owing to the commoner occurrence of disc pathologies. Concomittant appearance of a disc herniation and a neoplastic lesion

compromising the same nerve root represent a unique situation (Albert *et al.*, 1988; Cusimano *et al.*, 1995).

Lumbar disc herniations are often distinguished from other masses by their magnetic resonance (MR) signal characteristics (Table 1) (Tekkok *et al.*, 2004). We herein describe the case of a far-lateral extraforaminal periganglionic mass which was radiologically presumed to represent a right L4 nerve root schwannoma.

Case report

A 46-year-old woman presented with one-month history of low back and right leg pain which extended to knee and medial anterior tibial region. Pain was a burning pain often with electrical discharges. Right knee MR scan and lower limb venous doppler was normal. On admission, the right knee extension was weaker (3+/5). Hyperalgesia and loss of heat sensation were found over the right L4 dermatome. Right patellar reflex was absent. Lumbar MR scan showed L4-5 right extraforaminal bilobulated mass which measured 30 × 15 mm located extradurally antero-infero-medial to the L4 dorsal root ganglion (DRG). The mass was isointense on T1-weighted and hyperintense on T2 weighted MR images. Axial T1 and T2-weighted slices through the L4-5 interspace showed that there was questionable continuity with the disc space and that the fat plane around the DRG was obliterated. The lesion enhanced homogeneously after gadolinium injection (Fig. 1). The nerve root was extremely edematous on T2-TIRM (Turbo inversion recovery magnitude) MR images. The mass did not cause foraminal enlargement or destruction. Lack of dural tail on MR images supported the pre-operative diagnosis of a nerve sheath tumour. Acute and chronic denervation of right L3 and L4 nerves were documented by electromyography (EMG).

Table 1
Differential diagnosis of a lumbar extradural lesion based on MRI with contrast

	Enhancement with gadolinium-DTPA
Benign masses	
Cavernous hemangioma	Homogenous enhancement
Disc herniation	None or peripheral enhancement
Schwannoma	Heterogenous enhancement with a rim
Angiolipoma	Homogenous enhancement
Osteochondroma	None or minimal enhancement
Synovial cyst	None or peripheral enhancement
Malignant masses	
Metastasis	
Lymphomas	Marked and homogenous enhancement
Chordomas	Marked and homogenous enhancement
Ewing's sarcoma	Marked and homogenous enhancement

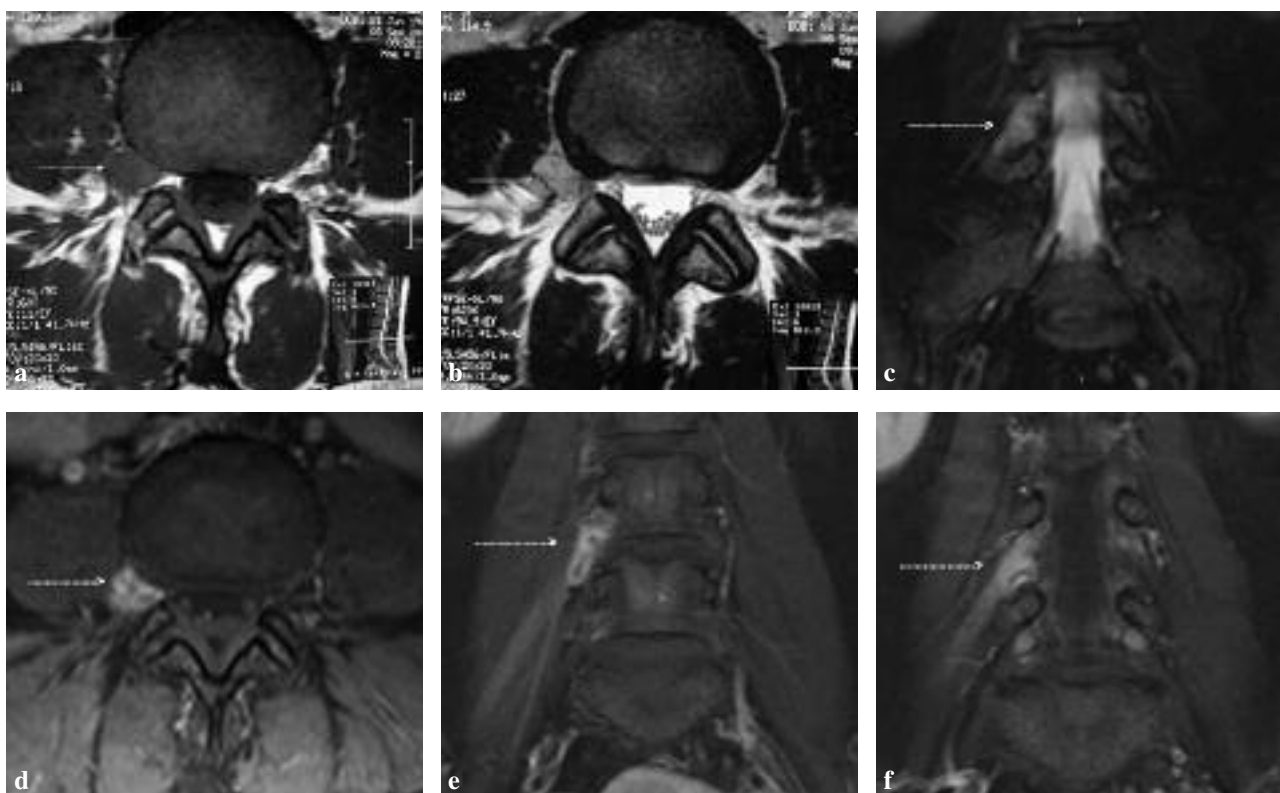


FIG. 1. — (a and b) Transverse T1 and T2 WI; (c) coronal T2 WI; (d, e and f) transverse and coronal T1 WI with gadolinium-DTPA show the mass (identified with red arrow) confused with a nerve sheath tumour, respectively.

She was then taken for surgery and through a right L4 hemilaminectomy and right L5 superior and L4 inferior facetectomies the L4 root was followed from the its origin into the extraspinal space. Both the L4 root and its DRG were immobile and edematous. Medial and anterior to the DRG, a bilobulated yellowish encapsulated mass was found and when its capsule was punctured a 25 × 15 mm cartilagenous

tissue was removed en bloc (Fig. 2). Next the DRG sheath was opened and the contents were found to be normal except for edema. Sheath was left open with a piece of Surgicell left over opening. Although the lateral ligament was intact, L4-5 disc was emptied. Histopathologic diagnosis of the removed mass was degenerated disc material with a wide peripheral neovascularization zone.

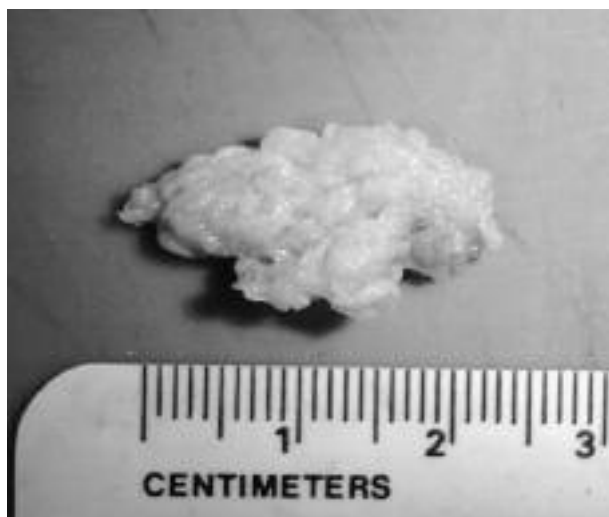


FIG. 2. — Surgically removed mass

The patient was discharged with 90/90 Karnofsky performance score. The postoperative early course was uneventful but after 2 weeks the patient presented with intense burning sensation around the right knee. Oral glucocorticoids was necessary to alleviate her dysesthesia. At 1 month postoperatively a postoperative MR scan was obtained to make sure operative site was clean which showed no residual disc material in the operative site (Fig. 3). Her dysesthesia eventually faded and gone. Neurologic examination at 9 months demonstrated normal neurological findings except an absent knee jerk and she remains pain and dysesthesia-free enjoying full range of activity.

Discussion

Far lateral (foraminal and extraforaminal) lumbar disc herniations represent only 1-11.7% of all disc herniations (Grenier *et al.*, 1990). Differential diagnosis of pathologies around and/or within the nerve ganglion include neural or dural sheath tumors (such as schwannoma or meningioma), metastatic diseases, lymphoma, conjoined nerve root abnormalities, extradural abscess and retroperitoneal tumours (Tekkok & Ruacan, 2006; Cusimano *et al.*, 1995). MR is the ideal imaging technique to demonstrate foraminal and extraforaminal structures especially if complemented with gadolinium-DTPA injection. A sequestered disc will appear as low signal intensity on T1-WI and hyperintensity on T2-WI because the fragment may still have a water content or reparative processes may lead to transient water gain. On contrast-enhanced MR scans, a sequestered or a fragmented lumbar intervertebral disc will exhibit

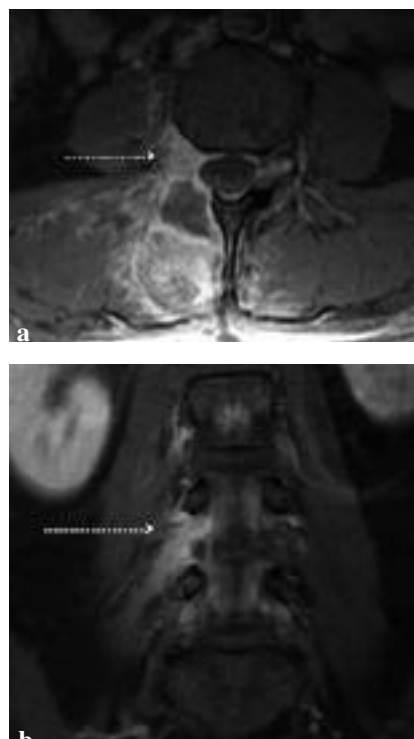


FIG. 3. — (a) Transverse T1 WI with gadolinium and (b) coronal T1 WI with gadolinium MR scan show no residual disc material at the operation area (identified with red arrow), respectively.

peripheral enhancement surrounding the non-enhancing cartilagenous material. This peripheral enhancement is best explained with inflammatory response and neovascularization around the sequestered tissue (Chen *et al.*, 2006; Lakshmanan *et al.*, 2006). Schwannomas on the other hand often appear compact and hypointense than the surrounding CSF on T1-WI and mild to markedly hyperintense on T2-WI. After contrast injection schwannomas enhance homogenously (Friedman *et al.*, 1992; Sze, 1991; Yamashita *et al.*, 1994). Although schwannomas represent approximately one-third of the all primary spinal neoplasms they are nevertheless rare with a yearly occurrence of 0.3-3.3 per 100 000 population (Grenier *et al.*, 1990). In our patient the mass was seen isointense on T1-WI; mild hypo- and isointense on T2-WI and enhanced homogenously after contrast injection. These radiological properties initially led us to suspect an extraspinal tumour since a herniated free disc fragment rarely enhances homogenously. Homogenous enhancement of disc material in our case was probably caused by chronic vascular granulation infiltrating into the sequestered disc. When that is the case such disc fragments may hardly be distinguished from tumours (D'Andrea *et al.*, 2004).

Conclusion

Chronic extreme lateral disc herniations may mimic tumoral masses from which they may be difficult to distinguish by the MRI.

REFERENCES

- Albert FK, Oldenkott P, Bieker G, Danz B. Lumbar intervertebral disk herniation with a concomitant nerve root neurinoma at the same site. Case report and review of the literature. *Neurochirurgia*. 1988;31:222-225
- Chen CY, Chuang YL, Yao MS, Chiu WT, Chen CL. *et al.* Posterior epidural migration of a sequestered lumbar disk fragment: MR imaging findings. *AJNR Am J Neuroradiol*. 2006;27:1592-1594.
- Cusimano MD, Bukala BP, Bilbao J. Extreme lateral disc herniation manifesting as nerve sheath tumor. Case report. *J Neurosurg*. 1995;82:654-656.
- D'Andrea G, Trillò G, Roperto R, Celli P, Orlando ER. *et al.* Intradural lumbar disc herniations: the role of MRI in preoperative diagnosis and review of the literature. *Neurosurg Rev*. 2004;27:75-82.
- Friedman DP, Tartaglino LM, Flanders AE. Intradural schwannomas of the spine: MR findings with emphasis on contrast-enhancement characteristics. *AJR Am J Roentgenol*. 1992;158:1347-1350.
- Grenier N, Gréselle JF, Douws C, Vital JM, Sénégas J. *et al.* MR imaging of foraminal and extraforaminal lumbar disk herniations. *J Comput Assist Tomogr*. 1990;14:243-249.
- Lakshmanan P, Ahuja S, Lyons K, Howes J, Davies PR. Sequestered lumbar intervertebral disc in the posterior epidural space: a report on two cases and review of the literature. *Spine J*. 2006;6:583-586.
- Sze G. Magnetic resonance imaging in the evaluation of spinal tumors. *Cancer*. 1991;67(Suppl. 4):1229-1241.
- Tekkok IH, Akpınar G, Gungen Y. Extradural lumbosacral cavernous hemangioma. *Eur Spine J*. 2004;13:469-473.
- Tekkok IH, Ruacan S. Dorsal root ganglionectomy for pseudotumor of the L3 dorsal root ganglion: a rare case and a rare treatment. *Eur Spine J*. 2004;15(Suppl. 5):610-615.
- Yamashita K, Hiroshima K, Kurata A. Gadolinium-DTPA-enhanced magnetic resonance imaging of a sequestered lumbar intervertebral disc and its correlation with pathologic findings. *Spine*. 1994;19:479-482.

Bulent Bakar, M.D.,
Kirikkale University,
School of Medicine
Dept. of Neurosurgery,
71100 Kirikkale (Turkey).
E-mail: bulentbanrs@yahoo.com