

## Neuropathology of some hereditary conditions affecting central and peripheral nervous system

J.-J. MARTIN and C. CEUTERICK

Born-Bunge Foundation and University of Antwerp

### Abstract

*Neuropathology plays a crucial role in the phenotypic individualization of hereditary disorders affecting the central and peripheral nervous system even if molecular genetics represents the most essential step in describing the genotypes. The neuropathological description of phenotypes and genotypes can be used for refining clinical skills and understanding many clinical, neurophysiological and neuroradiological features. It contributes to the diagnosis of such disorders. The use of immunohistochemical techniques in combination with molecular genetics improves also our knowledge of their pathogenesis and might participate to the future development of therapeutic strategies.*

*We discuss new features of spino-cerebellar ataxia (SCA) type 7 and of a recently identified SCA17 in order to illustrate the significance of the neuronal intranuclear inclusions (NIIs) described in various CAG/polyglutamine repeat expansion diseases. In the field of the peripheral neuropathies we present data on a newly described autosomal recessive Charcot-Marie-Tooth disease (CMT4F) with mutations in the periaxin gene. We document a dysjunction between myelin loops and axolemma with disappearance of the septate-like junctions or transverse bands. The significance of this dysjunction is not yet elucidated.*

*We hope to show by these examples that the combination of classical and new neuropathological methods is useful in the study of hereditary disorders of the nervous system.*

**Key words :** Spino-cerebellar ataxias ; Neuronal intranuclear inclusions ; Charcot-Marie-Tooth disease ; Periaxin ; Septate-like junctions or transverse bands.

### Introduction

Neuropathology has played a major role in defining the phenotypic appearances of hereditary disorders affecting the central and peripheral nervous system. However its methodological limitations are numerous : (1) During the life of the patients it has become more difficult to obtain biopsies because the diagnosis of the conditions can often be realized by other means. It is therefore impossible to justify invasive biopsies on ethical

grounds. One can still use skin-, conjunctival- and skeletal muscle biopsies but their best results are obtained when dealing with progressive metabolic disorders. The indications for peripheral nerve biopsies have to be assessed with much care as everyone knows and brain biopsies are no longer ethically justified. (2) The postmortem examination gives information on the end stage of the disorder and one misses a lot of intermediary steps. Functional brain imaging in first instance and neurophysiology offer compensatory means. (3) Neuropathology is very expensive and time consuming. (4) The use of modern techniques including electron microscopy and immunohistochemistry at light- and electron microscopic levels can only be applied to small specimens of tissue which may not be representative of the global picture. (5) Very careful clinical and neuropathological descriptions of phenotypes from the past are available but without clear identification of the genotype. On the other hand genotypes are now described for which full morphological data are not yet available.

The most obvious solution for a better correlation of the genotypes with neuropathology is to follow families during many generations, using new investigation techniques as soon as they become available. This is only possible in collaboration with clinicians, molecular geneticists, radiologists and the families regrouped in associations as this is now very often fortunately the case.

We have been able to do this in Antwerp since members of many affected families previously described by Dr. L. van Bogaert and his collaborators are still followed nowadays and because of the development of joint ventures with neurologists and other scientists from Belgium and abroad.

We could have planned a systematic neuropathological description of a series of representative conditions in this paper. However this would have required a booklet which would be hopelessly outdated at the time of publication. We have decided to use another philosophy by selecting only three conditions. We will attempt to demonstrate how an evaluation of classical data can be associated with

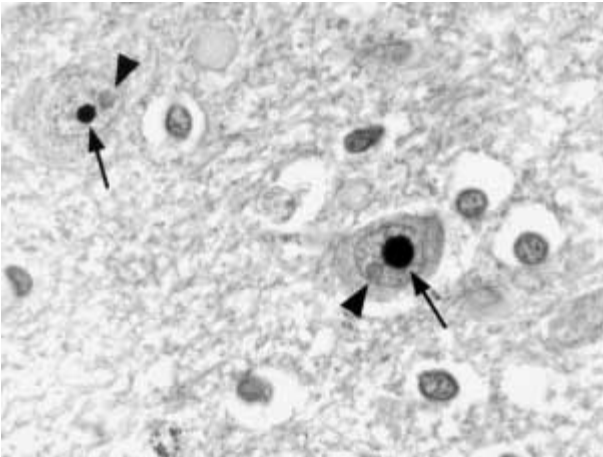


FIG. 1. — Spinocerebellar ataxia type 7 : presence of a unique immunostained intranuclear inclusion (arrows) in neurons belonging to the griseum pontis while the nucleolus (arrowheads) remains unstained (formol fixation, paraffin embedding, antibody against ataxin-7, magnification  $\times 760$ ).

new methods and concepts derived from the field of molecular genetics. We think that a combined approach contributes to a better understanding of the pathogenesis of such disorders and might open therapeutic perspectives.

### Central nervous system pathology

Major progresses have been made in the field of spinocerebellar ataxias since the publication of books on spinocerebellar degenerations (Greenfield, 1954) and hereditary ataxias (Harding, 1984) or of seminal papers such as the one on olivopontocerebellar atrophies (Konigsmark and Weiner, 1970). Classical neuropathology of CAG repeat diseases has been summarized by Robitaille *et al.* (1997). Their article gives an incomplete overview of the topic but a large number of papers are referenced. We will discuss two disorders not discussed by these authors and start with spinocerebellar ataxia type 7 (SCA7).

SCA7-causing mutation is invariably an expansion of a CAG triplet repeat within the coding region of the SCA7 gene, resulting in an expanded polyglutamine stretch in the corresponding protein, ataxin-7. It produces a gain-of-function, the precise mechanisms leading to neurodegeneration being not understood. One of the major morphological breakthroughs has been the identification of aggregates of polyglutamine-containing proteins in the nuclei but also in the cytoplasm of the affected neurons. This has suggested a direct pathological role for these aggregates e.g. by sequestration of critical cellular proteins. However the importance of aggregate formation has since then been questioned. In SCA7 the main lesions affect the retina, the spinocerebellar and olivocerebellar tracts, the cerebellar cortex, the brachia conjunctiva, the pyra-

midal pathways, the motor neurons of brain stem and spinal cord, the posterior columns and to a much lesser extent the subthalamic nucleus and the pallidum (Martin *et al.*, 1994, 1999). Immunohistochemistry indicates that ataxin-7, a protein of unknown function coded by the SCA7 gene, accumulates as a single nuclear inclusion in cortical neurons, in pontine neurons (Fig. 1). It is also present in the ganglion cell layer, the inner and outer nuclear layers of the retina in affected children when the retina is not yet destroyed like in adult patients with  $> 50$  CAG repeats. The 1C2 antibody directed against expanded polyglutamines confirms the aggregation of mutant ataxin-7 in these neuronal intranuclear inclusions (NIIs). Ubiquitin is also present in the same aggregates, suggesting that mutant ataxin-7 is a target for ubiquitin-dependent proteolysis but resistant to removal. Electron microscopy using immunogold labelling shows that ataxin-7 immunoreactive NIIs appears as dense aggregates containing a mixture of granular and filamentous structures (Mauger *et al.*, 1999). Although NIIs are found in unaffected areas of the brain, the proportion of neurons with nuclear labelling is higher, on average, in regions with neuronal loss. However immunoreactivity is low in some vulnerable populations of neurons such as Purkinje cells (Cancel *et al.*, 2000) and is no longer present in severely affected retina when nearly all cells have disappeared.

As a second example we will report on a very recently described autosomal dominant cerebellar ataxia with CAG repeat expansions in the TATA box-binding protein gene, an important general transcription factor, essential for the expression of most, if not all, protein-encoding genes (Fujigasaki *et al.*, 2001). Located on chromosome 6q27, CAG/CAA repeat expansion in the TBP gene causes the disorder (46-63 repeats are necessary with a normal range from 29 to 40 units). After the report of one sporadic case by Koide *et al.* (1999) and of two German families with an autosomal dominant ataxia (Zuhlke *et al.*, 2001), Fujigasaki *et al.* (2001) described a Flemish family with a similar genetic defect. This condition is now known as SCA17. Clinical features in six patients were cerebellar ataxia, dementia, psychosis and behavioural disturbances, with onset in the fourth to the sixth decade. Inheritance was autosomal dominant. We were fortunate enough to obtain a postmortem on one adult female patient belonging to the family. There was a marked cerebellar atrophy with loss of Purkinje cells but without features of olivopontocerebellar or spinocerebellar atrophy. Different antibodies (1C2, anti-TBP, anti-ubiquitin, anti-heat shock protein) revealed the presence of NIIs in different locations corresponding to *affected or unaffected* areas : pyramidal cells of Sommer's sector in the hippocampus and in the subiculum, many neocortical areas, the supraoptic hypothalamic nucleus, the

putamen, the cerebellar dentate nucleus, the griseum pontis, the nucleus ambiguus in the medulla oblongata and the anterior horns in the spinal cord. In the dentate nucleus, 1C2 also recognized perinuclear aggregates and in addition several 1C2-positive nuclei were seen in the granule cells of the cerebellar granular layer. TBP-positive nuclei were observed in neurons in the striatum. Since nearly all Purkinje cells had disappeared, no NIIs could be found in such cells.

We would like to concentrate on the presence of these NIIs since they do not only represent an elegant way to detect SCAs with expansion of trinucleotide repeats but may also contribute to unravel the pathogenesis of the disorders under consideration. They are not specific for a given type of SCA since their presence has also been reported in Huntington disease, in SCA1, 2, 3, 6, 7 and in dentatorubro-pallidolusian atrophy (DRPLA). However they may present some different characteristics in those different disorders and react to specifically developed antibodies directed against the gene products.

#### *General features of the neuronal intranuclear inclusions*

(1) it is a common feature of expanded CAG repeats causing neurodegenerative disorders but they may be absent ; (2) they are present in neuronal nuclei but other aggregates may be present in neuronal perikarya and in glial cells ; (3) they are present in (a) relatively small amounts and (b) in normal and abnormal areas of the CNS ; (4) they are detected by 1C2 antibodies or by antibodies directed to the specific gene product ; (5) they contain ubiquitin, proteasome components, heat shock protein (belonging to the major class of molecular chaperones responsible for modulating protein folding in the cell) but there is no immunoreactivity for cytoskeletal proteins. Activated caspase-3 should be checked to look for apoptosis.

The topography of the inclusions does not quite parallel the severity of the neuronal loss since they could be found in high numbers in regions considered to be little affected. It is of course very difficult to determine the course of neuronal death over time. Inclusions could have been very numerous in areas in which neuronal death had already taken place well *before* death and therefore *before* the histological study.

#### *General pathogenic mechanisms for the neurodegeneration*

Human cases, transgenic animals and cell-based models are available for the study of a number of polyglutamine repeat diseases. There is a toxic gain of function mediated by the mutant protein as a result of the expanded glutamine tract. It results in a dysfunction and the subsequent death of neurons.

Knock-out mouse models do not reproduce the disease phenotype, ruling out a simple dominant-negative or loss of function mechanism.

The nuclear localization seems to be a critical event leading to neuronal dysfunction. Hypotheses may be formulated : (1) the expanded polyglutamine domain may alter nuclear import or export of the diseased protein ; (2) or polyglutamine expansion could modify interactions with nuclear proteins, altering their function ; (3) or repeat expansion could result in a conformational change of the disease protein which alters susceptibility to proteolysis or exposes the polyglutamine domain, allowing it to form highly stable homotypic or heterotypic interactions. Parallelism has been drawn with what is supposed to happen in Creutzfeldt-Jakob disease, in which the normal form of the prion protein PrPc is converted into a pathological protease-resistant form PrPsc. It is however very difficult to explain the differential vulnerability of the neurons and this could be due to the involvement of interactive proteins such as the leucine-rich acidic nuclear protein (Ross, 1997).

#### *Significance of the aggregates*

A toxic effect of the aggregates was the first hypothesis to be put forward, based on following assumptions : (1) spatial disruption of coordinated nuclear processes such as transcription and splicing, (2) sequestering important nuclear factors thereby altering gene expression, (3) reflecting or provoking a breakdown of normal proteolytic processes within the nucleus, (4) ubiquitination of pathologic structures reflecting misfolding, aggregation or aberrant degradation of proteins.

But in fact NIIs do not seem to initiate pathogenesis since they are only found in rather small quantities and since there is no strict parallelism between their number and the severity of the pathology in humans. Studies on transfected cells show for example that inhibiting proteasomal degradation promotes ataxin-1 aggregation. In transgenic mice, Purkinje cells that express mutant ataxin-1 but *not* a ubiquitin-protein ligase have significantly fewer NIIs ; nonetheless the Purkinje cell pathology is markedly worse than that of the "simple" SCA1 mice (Cummings *et al.*, 1999). The formation of NIIs may initially sequester the toxic protein, thereby protecting the nucleus from its toxic effects.

A sequence of events has been proposed by Klement *et al.* (1999) for the spinocerebellar ataxia (SCA1) : (1) ataxin-1 passes through the cytoplasm "en route" to the nucleus ; (2) nuclear import of ataxin-1 is regulated by cell-specific factors and in Purkinje cells is dependent on a nuclear localization sequence (NLS) in the C' region containing a basic cluster. Ataxin-1 is not pathogenic without a functional NLS ; (3) in the nucleus, the N' and

polyQ epitopes are lost perhaps due to conformational change or protein binding. A pathogenic gain of function is conferred on ataxin-1; (4) pathogenic ataxin-1 eventually collects as insoluble aggregates. The self-association region is essential for aggregation formation but not for initiation of the pathogenesis. The presence of ubiquitin within the aggregates suggests that they may arise from ataxin-1 misfolding and subsequent ineffectual turnover by the proteasome system. It is possible that the aggregates mediate a pathogenic effect that is distinct from that of the soluble form of ataxin-1. If so, then this effect is not necessary for the initiation of the pathogenesis but may have a role in disease progression. Therapeutic perspectives may be opened by blocking nuclear translocation or interfering in the nucleus on specific interactions that transform expanded ataxin-1 to a pathogenic form. Up to now and in conclusion, the molecular mechanisms underlying the selective neuronal death are in fact unknown. Possible final common paths leading to cell death would be classical apoptosis or autophagy (apoptosis type II).

### Peripheral nervous system pathology

After the description of Charcot-Marie-Tooth disease (CMT) in 1886, it soon became apparent that this syndrome was clinically and genetically heterogeneous with various modes of inheritance. Modern molecular genetics investigations have proven this assumption.

The identification of pathogenic mutations in new genes is a continuous process as shown by De Jonghe *et al.* (2000 and this symposium) or by Meuleman *et al.* (2000) and present research indicates that this proposition holds true.

Neuropathology has of course played initially a role in defining the phenotypic expressions of CMT. Most of the reports describe classic onion bulbs around naked axons, remyelinating axons or normally myelinated axons. Other onion bulbs are characterized by a proliferation of the basal lamina or are said to be obsolete when the central axon has completely disappeared. Descriptions are given of tomacula, outfolding of myelin sheaths, focally folded myelin sheaths etc. In some circumstances such as in Po mutations, widening of myelin lamellae may be observed. Such alterations are not specific for CMT1B and can for example be found in IgM and IgA monoclonal gammopathies (Vallat *et al.*, 2000). These data can be correlated with electromyography. In another register the existence of CMT due to a gene encoding a non compact myelin gap junction protein (GJB1) indicates that our attention should also be paid to the nodes of Ranvier since they feature a very crucial connection between axons and myelin sheaths.

Important information may result from a renewed study of peripheral nerve biopsies even if

they have been performed many years ago and we are experimenting it nearly every day. With the development of the diagnostic molecular genetics, it is more difficult nowadays to perform as much peripheral nerve biopsies as in the past. Among new methods which can be applied to biopsies, immunohistochemistry at light and electron microscopic level could sometimes justify a new nerve biopsy. Alternatively we think that the examination of cutaneous nerve twigs obtained by a skin biopsy could replace it, at least in part, and will endeavor to demonstrate it in the near future. Some methods may also be applied to old deep-frozen or embedded material as we will show now.

We want to illustrate the retrieval of important information in old biopsies by discussing an autosomal recessive form of CMT classified as CMT4F, due to mutations in the periaxin (PRX) gene. The PRX gene encodes two proteins L- and S-periaxin that are required for maintenance of peripheral nerve myelin. It is mapped to 19q13.13-13.2. PRX is expressed by myelinating Schwann cells. As myelin matures, PRX becomes predominantly localized at the abaxonal membrane which suggests that it might participate to the stabilization of the mature sheaths. An autosomal recessive CMT4F (Delague *et al.*, 2000; Guilbot *et al.*, 2001) or an autosomal recessive Déjerine-Sottas neuropathy with a severe sensory component (Boerkoel *et al.*, 2001) due to periaxin mutations have been described recently. Histology showed "onion-bulb" structures and "hypermyelinated" sheaths. Other families are now in the process of being reported (Takashima *et al.*, in press) confirming that periaxin mutations may cause a broad spectrum of demyelinating neuropathies. Extensive peripheral demyelination and neuropathic pain behaviour, allodynia (or pain from non-noxious stimuli) and hyperalgesia (or hypersensitivity to pain) have been described in periaxin-deficient mice (Gillespie *et al.*, 2000).

We have been able to review a nerve biopsy made in 1992 of a female patient with a familial peripheral neuropathy. The parents were consanguineous. An affected brother had been examined recently. He was severely handicapped and scoliotic like his sister. The peripheral neuropathy included severe sensory disturbances. An homozygous PRX mutation was found in both patients.

The sural nerve biopsy was re-examined in 2001. There was a very severe demyelination with a few remaining myelinated internodes and some tomacula stained by the modified Gomori's trichrome and by antibodies against myelin basic protein, peripheral myelin protein 22 and protein P0. The use of antibodies made against various epitopes of periaxin obtained in mice (Brophy and Williams, personal communication) showed an immunoreactivity for the N terminal and the central repeat region of periaxin but not for the

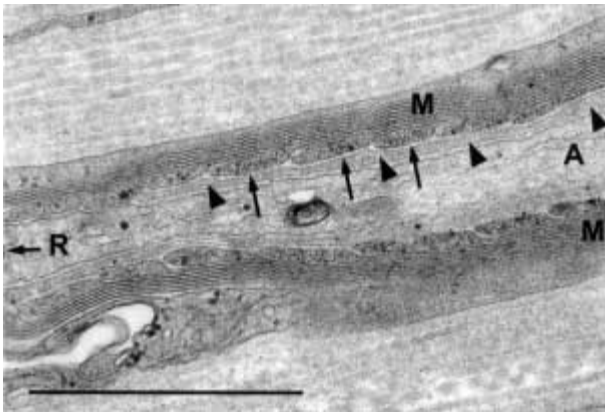


FIG. 2. — Peripheral nerve biopsy in a female patient with a periaxin-deficient neuropathy. Heminode of Ranvier (R) with disappearance of the septate-like junctions attaching the myelin loops to the axolemma (A) (arrows). A Schwann cell process (arrowheads) detaches the myelin loops (M) from the axon (glutaraldehyde fixation, araldite embedding, uranyl-acetate and lead citrate staining, scale = 1  $\mu$ m).

C-terminus, indicating that a truncated protein was made.

Light microscopy of semi-thin resin sections and electron microscopy confirmed a severe loss of myelinated axons of all diameters. Tomacula consisted of concentric or eccentric thickenings of the myelin sheath with sometimes focally folded myelin surrounding a constricted axon. The onion bulbs were made up of concentrically arranged Schwann cell processes around a myelinated, hypermyelinated or less frequently, a thinly myelinated axon. Some onion bulbs were denervated and showed increased amounts of collagen fibres. Redundant basal laminae were noted in few classical onion bulbs. Rare myelin debris were found in Schwann cells. There were no abnormalities of the myelin packing. Some distended unmyelinated axons had a diameter of 2.5  $\mu$ m. Denervated Schwann cell units of unmyelinated axons enclosed collagen pockets. A massive increase of endoneurial collagen fibres was observed.

Special attention was paid to the longitudinal investigation of paranodal myelin of fibres with normal myelin sheath thickness. Paranodal myelin loops had an irregular aspect. The number of myelin loops was reduced, most loops were short and no paranodal desmosome-like structures were seen between these terminal loops. Moreover, no direct or interrupted contacts between paranodal myelin loops and axon were found. At these sites, transverse bands or septate-like junctions were absent or irregularly present. Sometimes, paranodal myelin loops and axon were separated by a Schwann cell process lying between them (Fig. 2). There was a detachment of terminal myelin loops from the axon by the Schwann cell process. In conclusion, neuropathology was remarkable for tomacula formation with focal myelin thickening,

abnormalities of the paranodal loop and *absence* or *disappearance* of septate-like junctions or transverse bands linking myelin loops to the axon. It is too early to decide whether this axo-schwannian dysjunction indicates a primary developmental deficiency or whether it represents only a non-specific paranodal demyelination.

Recent work (Sherman *et al.*, 2001) has shown the presence of a dystroglycan-dystrophin-related protein 2 (DRP2) complex at the surface of myelin-forming Schwann cells in mice. This complex interacts with L-periaxin. In the absence of L-periaxin, DRP2 is mislocalized and its disruption is followed by hypermyelination and destabilization of the Schwann cell-axon unit. The authors suggest that the DRP2-dystroglycan complex has very likely a function in the terminal stages of myelogenesis, possibly in the regulation of the myelin thickness. It will certainly be important in the future to check the presence of dystrophin-dystroglycan complexes in Schwann cells by using available antibodies. Limb-girdle muscular dystrophies illustrate what can be obtained by such studies. Further characterization of these complexes will possibly enable us to identify new candidate genes for other forms of CMT.

## Conclusions

Neuropathology has still a major role to play in the study of the many different types of hereditary ataxias and peripheral neuropathies. Correlation of clinical phenotypes with the neuropathological features and of genotypes with neuropathology remains necessary to improve our diagnostic skills and to help understand clinical, radiological, neurophysiological and laboratory data. During the life of the patients, non-invasive skin biopsies should be done to study the cutaneous nerve twigs in order to apply light- and electron microscopic immunohistochemical techniques. Postmortem examination has its limitations as already mentioned in the introduction but a combination of classical and modern neuropathological techniques may contribute to a better understanding of the pathogenesis of those disorders. The examination of transgenic animals and of cells in culture could certainly obviate the shortcomings of the autopsy.

## REFERENCES

- BOERKOEEL C. F., TAKASHIMA H., STANKIEWICZ P., GARCIA C. A., LEBER S. M. *et al.* Periaxin mutations cause recessive Déjerine-Sottas neuropathy. *Am. J. Hum. Genet.*, 2001, **68** : 325-333.
- CANCEL G., DUYSKAERTS C., HOLMBERG M., ZANDER C., YVERT G. *et al.* Distribution of ataxin-7 in normal human brain and retina. *Brain*, 2000, **123** : 2519-2530.
- CUMMINGS C. J., REINSTEIN E., SUN Y., ANTALFFY B., JIANG Y.-H. *et al.* Mutation of the E6-AP ubiquitin

- ligase reduces nuclear inclusion frequency while accelerating polyglutamine-induced pathology in SCA1 mice. *Neuron*, 1999, **24** : 879-892.
- DE JONGHE P., TIMMERMAN V., NELIS E. Hereditary peripheral neuropathies. In *Neuromuscular diseases : from basic mechanisms to clinical management*. Deymeer F. (ed.) Vol. 18. Basel, Karger, 2000, 128-146.
- DELAGUE V., BAREIL C., TUFFERY S., BOUVAGNET P., CHOUERY E. *et al.* Mapping of a new locus for autosomal recessive demyelinating Charcot-Marie-Tooth disease on 19q13.1-13.3 in a large consanguineous Lebanese family : exclusion of MAG as a candidate gene. *Am. J. Hum. Genet.*, 2000, **67** : 236-243.
- FUJIGASAKI H., MARTIN J.-J., DE DEYN P.-P., CAMUZAT A., DEFFOND D. *et al.* CAG repeat expansion in the TATA box-binding protein gene causes autosomal dominant cerebellar ataxia. *Brain*, 2001, **124** : 1939-1947.
- GILLESPIE C. S., SHERMAN D. L., FLEETWOOD-WALKER S. M., COTTRELL D. F., TAIT S. *et al.* Peripheral demyelination and neuropathic pain behavior in periaxin-deficient mice. *Neuron*, 2000, **26** : 523-531.
- GREENFIELD J. G. *The spino-cerebellar degenerations*. Oxford, Blackwell Scientific Publications 1954. A book of 112 pages.
- GUILBOT A., WILLIAMS A., RAVISÉ N., VERNY C., BRICE A. *et al.* A mutation in periaxin is responsible for CMT4F, an autosomal recessive form of Charcot-Marie-Tooth disease. *Hum. Mol. Genet.*, 2001, **10** : 415-421.
- HARDING A. E. *The hereditary ataxias and related disorders*. Edinburgh, Churchill Livingstone, 1984. A book of 266 pages.
- KLEMENT I. A., ZOGHBI H. Y., ORR H. T. Pathogenesis of polyglutamine-induced disease : a model for SCA1. *Mol. Genet. Metab.*, 1999, **66** : 172-178.
- KOIDE R., KOBAYASHI S., SHIMOHATA T., IKEUCHI T., MARUYAMA M. *et al.* A neurological disease caused by an expanded CAG trinucleotide repeat in the TATA-binding protein gene : a new polyglutamine disease ? *Hum. Mol. Genet.*, 1999, **8** : 2047-2053.
- KONIGSMARK B. W., WEINER L. P. *The olivopontocerebellar atrophies : a review*. *Medicine*, 1970, **49** : 227-241.
- MARTIN J.-J., VAN REGEMORTER N., KROLS L., BRUCHER J.-M., DE BARSY T. *et al.* On an autosomal dominant form of retino-cerebellar degeneration : an autopsy study of five patients in one family. *Acta Neuropathol.*, 1994, **88** : 277-286.
- MARTIN J.-J., VAN REGEMORTER N., DEL-FAVERO J., LÖFGREN A., VAN BROECKHOVEN C. Spinocerebellar ataxia type 7 (SCA7) – correlations between phenotype and genotype in one large Belgian family. *J. Neurol. Sci.*, 1999, **168** : 37-46.
- MAUGER C., DEL-FAVERO J., CEUTERICK C., LÜBKE U., VAN BROECKHOVEN C. *et al.* Identification and localization of ataxin-7 in brain and retina of a patient with cerebellar ataxia type II using anti-peptide antibody. *Mol. Brain Res.*, 1999, **74** : 35-43.
- MEULEMAN J., TIMMERMAN V., NELIS E., DE JONGHE P. Molecular genetics of inherited peripheral neuropathies : who are the actors ? *Acta Neurol. Belg.*, 2000, **100** : 171-180.
- ROBITAILLE Y., LOPES-CENDES I., BECHER M., ROULEAU G., CLARK A. W. The neuropathology of CAG repeat diseases : review and update of genetic and molecular features. *Brain Pathol.*, 1997, **7** : 901-926.
- ROSS C. A. Intranuclear neuronal inclusions : a common pathogenic mechanism for glutamine-repeat neurodegenerative diseases ? *Neuron*, 1997, **19** : 1147-1150.
- SHERMAN D. L., FABRIZI C., GILLESPIE C. S., BROPHY P. J. Specific disruption of a Schwann cell-dystrophin related protein complex in a demyelinating neuropathy. *Neuron*, 2001, **30** : 677-687.
- TAKASHIMA H., BOERKOEL C. F., DE JONGHE P., CEUTERICK C., MARTIN J.-J. *et al.* Periaxin mutations cause a broad spectrum of demyelinating neuropathies. *Ann. Neurol.* In press.
- VALLAT J.-M., TABARAUD F., SINDOU P., PREUX P.-M., VANDENBERGHE A. *et al.* Myelin widenings and MGUS-IgA : An immunoelectron microscopic study. *Ann. Neurol.*, 2000, **47** : 808-811.
- ZUHLKE C., HELLENBROICH Y., DULSKI A., KONONOWA N., HAGENAH J. *et al.* Different types of repeat expansion of the TATA-binding protein gene are associated with a new form of inherited ataxia. *Eur. J. Hum. Genet.*, 2001, **9** : 160-164.

J.-J. MARTIN,  
Born-Bunge Stichting,  
Gebouw T – Lokaal 5.18,  
Universitaire Instelling Antwerpen,  
Universiteitsplein 1,  
B-2610 Wilrijk (Belgium).  
E-mail : jjmneuro@uia.ua.ac.be