

Recent developments in the neuropathological diagnosis of Parkinson's disease and parkinsonism

A. MICHOTTE

Departments of Neurology and Pathology (Neuropathology), AZ-VUB

Abstract

The diagnosis of Parkinson's disease (PD) is based mainly on clinical criteria. Large clinicopathological studies reveal however a different diagnosis in up to 25% of the cases (Hughes et al., 1992). Recent advances in molecular biology have shown that some proteins, especially tau and alpha-synuclein, play an essential role in the pathogenesis of parkinsonian and dementing disorders. Such diseases are now classified as tauopathies and synucleinopathies. Progressive supranuclear palsy and corticobasal degeneration are the major tauopathies. To the synucleinopathies belong PD, Lewy body dementia and multiple system atrophy. In pathological conditions abnormal proteins will aggregate in neurons and glial cells and form inclusion bodies. Lewy bodies are the hallmark of Parkinson's disease and Lewy body dementia. Identification of these inclusions and other specific lesions in parkinsonian disorders is facilitated by the routine application on formalin fixed brain of immunohistochemistry for alpha-synuclein, tau and ubiquitin. The purpose of this paper is to briefly review and illustrate the value of these new techniques in the postmortem diagnosis of parkinsonian disorders. Neuropathological examination of the brain is however time consuming and immunohistochemistry represents additional costs. As the selection of brain samples for microscopical examination and antibodies for immunohistochemistry depends on the underlying pathology, some clinical information should be provided to the pathologist such as the clinical diagnosis and when indicated the results of brain imaging studies. A close co-operation between the neurologist and neuropathologist is thus essential to select the most appropriate brains for complete neuropathological investigation.

Key words : Parkinson, parkinsonism, Lewy body, alpha-synuclein, ubiquitin, neuropathology, pathogenesis.

Neuropathology of Parkinson's disease

Parkinson's disease is pathologically characterised by loss of pigmented neurons in the pars compacta of the substantia nigra and locus coeruleus associated with astrocytic gliosis and free pigment in the neuropil (Forno, 1996 ; Lowe

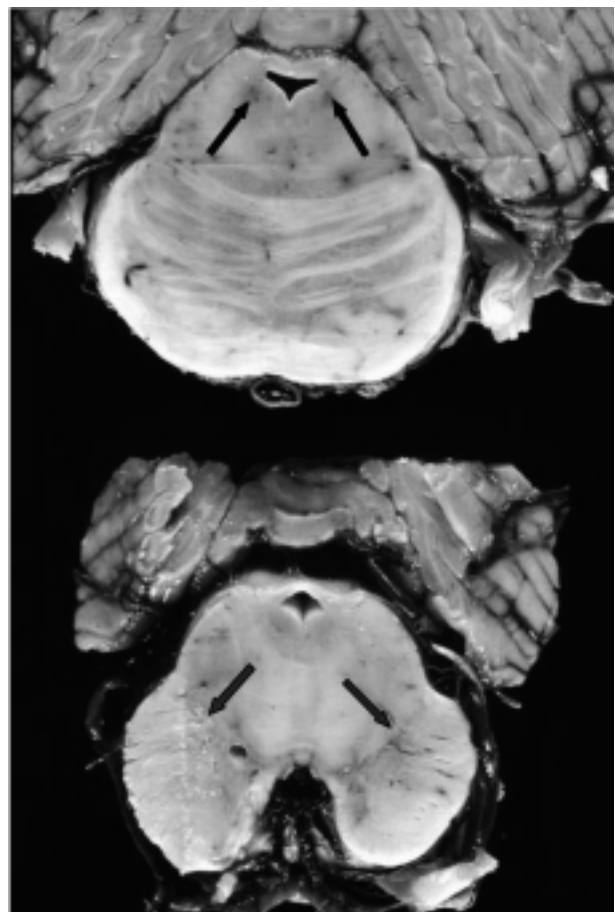


FIG. 1. — Parkinson's disease. Pale appearance of the locus niger and locus coeruleus (arrows).

and Leigh, 2002). This explains the pale appearance of these nuclei observed on gross examination of the brain (Fig. 1). The pathological hallmark of PD is the Lewy body (Forno, 1996 ; Lowe and Leigh, 2002), first described by Lewy in 1912. Its presence is not restricted to the locus niger. Extranigral sites are also affected, some of them at an early stage of the disease. Lewy bodies can be

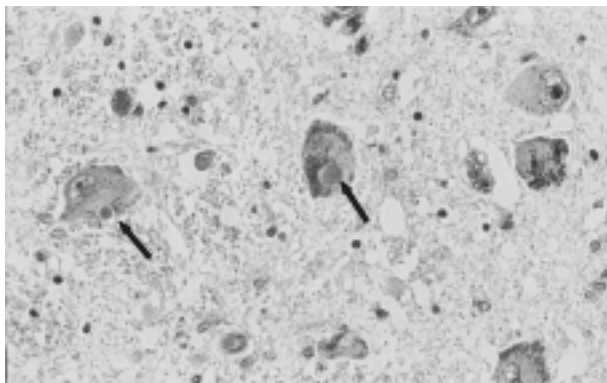


FIG. 2. — Photomicrograph of the locus niger showing two Lewy bodies (arrows), neuronal loss and free pigment in the neuropil. Hematoxylin-Eosin, original magnification $\times 250$.

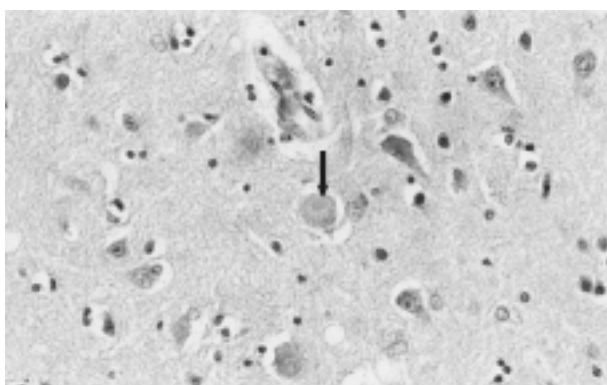


FIG. 3. — Photomicrograph of a cortical Lewy body (arrow) in the deep neuronal layers of the temporal cortex. Hematoxylin-Eosin, original magnification $\times 300$.

observed in the locus coeruleus, the nucleus basalis of Meynert, the hypothalamus, the olfactory bulb, the dorsal vagal nucleus, the intermediolateral column in the spinal cord and even in ganglia of parasympathetic and sympathetic nervous system where their presence may explain some clinical features such as orthostatic hypotension and dysphagia or hyposmia which has been described as an early phenomenon in PD (Del Tredici *et al.*, 2002). Two types of Lewy bodies may be seen: the brainstem or classical type found in idiopathic PD and the cortical type observed in Lewy body dementia (Lowe and Leigh, 2002). The classical Lewy body is a cytoplasmic, eosinophilic, often round inclusion with a size ranging from 3 to 20 μm , typically surrounded by a clear halo (Fig. 2). The cortical type is less well defined and lacks an obvious halo (Fig. 3). It is encountered usually in neurons of the deep layers of temporal, insular and cingulate cortex. Lewy bodies are however not specific for PD and can also be found as a secondary pathology in several disorders like Alzheimer's disease, multiple system atrophy, progressive supranuclear palsy and corticobasal degeneration (Lowe and Leigh, 2002). Pale bodies are considered as the precursors of Lewy

bodies. They are seen in pigmented neurons of locus niger and coeruleus as granular, pale-staining material which displaces the neuromelanin.

Proteins involved in LB formation and their role in pathogenesis of PD

Recent advances in molecular biology and the study of familial cases of parkinsonism and dementia lead to the identification of genes and proteins involved in the pathogenesis of these diseases (Mouradian, 2002). Lewy bodies contain aggregates of many different proteins mainly alpha-synuclein, ubiquitin and its related proteins UCH-L1 and parkin but also synphilin, a β crystallin, b-amyloid precursor protein and probably other still unidentified proteins.

ALPHA-SYNUCLEIN

Alpha-synuclein was identified in 1993 as a non-beta amyloid component peptide (NACP) of senile plaques. It contains 140 amino acids and is concentrated in the presynaptic nerve terminals where it is thought to play a role in neuronal plasticity. In 1997 Polymeropoulos *et al.* described families of Italian and Greek origin with an autosomal dominant transmitted Parkinson's disease (PARK 1) due to a point mutation (ala53thr) in the alpha-synuclein gene located on the long arm of chromosome 4 (4q21-q23). A year later a second mutation (ala30pro) was identified in a German family (Kruger *et al.*, 1998). Several members of these families present L-dopa responsive Parkinson's disease with early onset. At autopsy typical neuropathological features with Lewy bodies are found. It was shown that alpha-synuclein is the major component of both types of Lewy bodies not only in familial forms of Parkinson's disease but also in the sporadic cases and in Lewy body dementia (Spillantini *et al.*, 1997). Alpha-synuclein thus seems to play a major role in the formation of Lewy bodies. Mutations in its gene or the influence of environmental factors such as some toxins and pesticides responsible for mitochondrial dysfunction and subsequent oxidative stress will cause a conformational change of alpha-synuclein into insoluble fibrillar aggregates. High concentrations of these aggregates will lead to the formation of Lewy bodies (Lowe and Leigh, 2002; Betarbet *et al.*, 2002). Modern neuropathological techniques now include immunohistochemistry with antibodies against alpha-synuclein for a better identification of Lewy bodies (Fig. 4) and Lewy neurites. Lewy neurites are abnormal neurites found in areas undergoing neuronal degeneration with Lewy bodies. They are barely visible with standard staining methods (Lowe and Leigh, 2002). Accumulation of alpha-synuclein in pathological inclusions is not limited to Parkinson's disease (Mouradian, 2002).

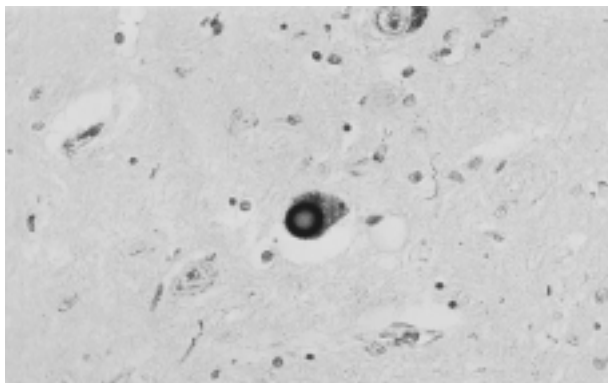


FIG. 4. — Photomicrograph of a classical Lewy body in the locus niger with strong immunoreactivity for alpha-synuclein. Immunohistochemistry for alpha-synuclein, original magnification $\times 300$.

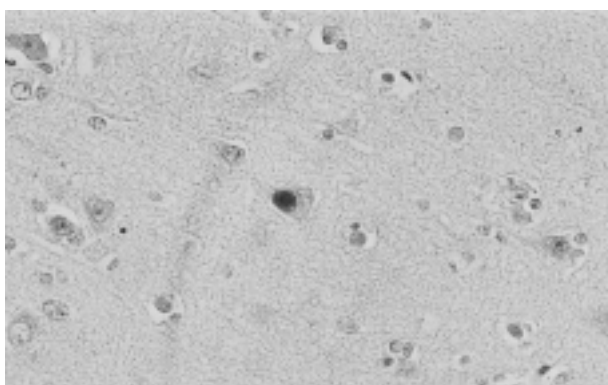


FIG. 5. — Photomicrograph of a cortical Lewy body in the temporal cortex with strong immunoreactivity for ubiquitin. Immunohistochemistry for ubiquitin, original magnification $\times 400$.

Immunohistochemistry also demonstrates its presence in senile plaques of Alzheimer's disease and in the glial cytoplasmic inclusions of multisystem atrophy.

UBIQUITIN AND RELATED PROTEINS

Ubiquitin is a heat-shock protein, which play an important role in the non-lysosomal degradation of mutated or oxidatively damaged proteins (Betarbet *et al.*, 2002). Such abnormal proteins tend to aggregate as inclusions. Cells use the so-called ubiquitin/proteasome pathway (UPP) to eliminate those unwanted proteins. Most inclusions are ubiquitinated for example beta-amyloid in senile plaques, phosphorylated tau-protein in neurofibrillary tangles and Pick bodies and alpha-synuclein in Lewy bodies (Fig. 5). Ubiquitin needs the assistance of 3 enzymes for its normal functioning (Mouradian, 2002). The first enzyme is ubiquitin carboxyl-terminal hydrolase (UCH-L1) also known as PGP9.5, an activating enzyme that generates the ubiquitin monomer. Ubiquitin conjugating enzyme E2 helps in the transfer of ubiquitin. The third enzyme is E3 ubiquitin ligase, also known as Parkin, which

attaches ubiquitin to abnormal proteins preparing them for degradation. The importance of UPP in the formation of Lewy bodies is further stressed by the study of families with Parkinson's disease. Two members of a family were reported with early-onset autosomal dominant transmitted typical Parkinson's disease due to a mutation in the UCH-L1 gene located on chromosome 4p14 (PARK 5). (Leroy *et al.*, 1998). Several families were reported in Japan and in Europe with an autosomal recessive juvenile Parkinson's disease caused by mutations in the Parkin gene located on chromosome 6q25.2-27 (PARK 2) (Kitada *et al.* 1998, Tassin *et al.* 1998). Members of such families present with parkinsonism before the age of 40 years, often with dystonia, early and severe levodopa-induced dyskinesias and temporary improvement of symptoms after a period of rest. Neuropathological examination of the few autopsied cases show neuronal loss and gliosis confined to the substantia nigra pars compacta and locus coeruleus without Lewy bodies. This means that intact functional Parkin is important for the processing of alpha-synuclein and some other peptides and for the formation of Lewy bodies (Mouradian, 2002). Absence of Lewy bodies in these cases might also suggest that they are not the cause of Parkinson's disease but rather the expression of a cytoprotective response designed to eliminate damaged proteins.

Neuropathological differential diagnosis of parkinsonian disorders

Parkinson's disease, multiple system atrophy and progressive supranuclear palsy are the main causes of parkinsonism (Lowe and Leigh, 2002).

MULTIPLE SYSTEM ATROPHY

MSA encompasses the following neurodegenerative disorders : striatonigral degeneration (MSA-P), olivopontocerebellar atrophy (MSA-C) and Shy-Drager syndrome. MSA begins in adulthood and presents with varying degrees of parkinsonism, cerebellar dysfunction and autonomic failure. Gross examination of the brain shows atrophy of lower brainstem and cerebellum in MSA-C whereas in MSA-P a selective atrophy of the putamen is seen. Depigmentation of substantia nigra and locus coeruleus is seen in all MSA subtypes. Microscopic examination reveals neuronal loss, gliosis and microvacuolation within the involved neuronal systems. The histological hallmark of MSA are the glial cytoplasmic inclusions (GCIs) (Lowe and Leigh, 2002), defined as sickle- or flame-shaped inclusions in oligodendroglial cells with a strong immunoreactivity for alpha-synuclein. MSA thus belongs to the synucleinopathies. Neuronal cytoplasmic and nuclear inclusions may also be found.

PROGRESSIVE SUPRANUCLEAR PALSY

PSP is a tauopathy grossly characterised by atrophy of the mesencephalon and the pontine tegmentum with depigmentation of locus niger and coeruleus. Histological features include accumulation in neurons of the brain stem and basal ganglia of abnormal tau protein aggregates into neurofibrillary globose tangles associated with neuronal loss and gliosis. Tau also accumulates in astrocytes in the grey matter, the so-called tufted astrocytes and as coiled bodies in oligodendrocytes (Lowe and Leigh, 2002 ; Bergeron *et al.*, 1998)

CORTICOBASAL DEGENERATION

Macroscopically corticobasal degeneration (CBD) is characterised by a typically asymmetrical atrophy restricted to the posterior frontal and parietal cortex and by depigmentation of locus niger and coeruleus. CBD is like PSP also characterised by tau-immunopositive intraneuronal inclusions in brain stem and basal ganglia, which may look very similar to the globose tangles of PSP. The main pathological feature is the presence of abundant swollen cortical neurones also named achromatic or ballooned neurons, in the deep layers of the affected cortex. Other characteristic features are the tau-positive astrocytic plaques (Bergeron *et al.*, 1998).

OTHER NEUROPATHOLOGICAL DIAGNOSES
OF PARKINSONISM

Brain autopsy of patients with parkinsonism may reveal other pathologies such as Alzheimer's disease, frontotemporal dementia including Pick's disease and dementia lacking distinctive histology and other non-degenerative disorders such as status lacunaris and hydrocephalus (Lowe and Leigh, 2002).

Conclusion

The diagnosis of Parkinson's disease and other parkinsonian and dementing disorders may be difficult even when using well-defined clinical criteria. The definite diagnosis still relies on the post-mortem examination of the brain. Standard neuropathological examination of the brain of such patients should nowadays include the routine application of immunohistochemistry with antibodies against the major proteins involved in the neuropathogenesis of these disorders. This modern approach is however time consuming and expensive. A close collaboration between the clinician and the neuropathologist is thus essential to obtain a maximal benefit from neuropathological investigation.

REFERENCES

- BERGERON C., DAVIS A., LANG A. E. Corticobasal ganglionic degeneration and progressive supranuclear palsy presenting with cognitive decline. *Brain Pathology*, 1998, **8** : 355-365.
- BETARBET R., SHERER T. B., DI MONTE D. A., GREENAMYRE J. T. Mechanistic approaches to Parkinson's disease pathogenesis. *Brain Pathology*, 2002, **12** : 499-510.
- DEL TREDICI K., RÜB U., DE VOS R. A. I., BOHL J. R. E., BRAAK H. Where does Parkinson disease begin in the brain ? *J. Neuropathol. Exp. Neurol.*, 2002, **61** : 413-426.
- FORNO L. S. Neuropathology of Parkinson's disease. *J. Neuropathol. Exp. Neurol.*, 1996, **55** : 259-272.
- HUGHES A. J., DANIEL S. E., KILFORD L., LEES A. J. Accuracy of the clinical diagnosis of Parkinson's disease : a clinicopathological study of 100 cases. *J. Neurol. Neurosurg. Psychiatry*, 1992, **55** : 181-184.
- KITADA T., ASAKAWA S., HATTORI N., MATSUMINE H., YAMAMURA Y. *et al.* Mutations in the parkin gene cause autosomal recessive juvenile parkinsonism. *Nature*, 1998, **392** : 605-608.
- KRUGER R., KUHN W., MULLER T., WOITALLA D., GRAEBER M. *et al.* Ala30-to-pro mutation in the gene encoding alpha-synuclein in Parkinson's disease. *Nature Genet.*, 1998, **18** : 106-108.
- LEROY E., BOYER R., AUBURGER G., LEUBE B., ULM G. *et al.* The ubiquitin pathway in Parkinson's disease. *Nature*, 1998, **395** : 451-452.
- LOWE J. S., LEIGH N. Disorders of movement and system degenerations. In : *Greenfield's Neuropathology*. GRAHAM D. I., LANTOS P. L. (eds.), Chapter 6, 2002 : 325-430. Arnold : London, New York, New Delhi.
- MOURADIAN M. M. Recent advances in the genetics and pathogenesis of Parkinson disease. *Neurology*, 2002, **58** : 179-185.
- POLYMERPOULOS M. H., LAVEDAN C., LEROY E., IDE S. E., DEHEJIA A. *et al.* Mutation in the alpha-synuclein gene identified in families with Parkinson's disease. *Science*, 1997, **276** : 2045-2047.
- SPILLANTINI M. G., SCHMIDT M. L., LEE V. M. Y., TROJANOWSKI J. Q., JAKES R. *et al.* Alpha-synuclein in Lewy bodies. *Nature*, 1997, **388** : 839-840.
- TASSIN J., DURR A., DE BROUCKER T., ABBAS N., BONIFATI V. *et al.* Chromosome 6-linked autosomal recessive early-onset parkinsonism : linkage in European and Algerian families, extension of the clinical spectrum, and evidence of a small homozygous deletion in one family. *Am. J. Hum. Genet.*, 1998, **63** : 88-94.

A. MICHOTTE,
AZ-VUB,
Dept of Neurology and Pathology,
Laarbeeklaan, 101,
B-1090 Brussel (Belgium).
E-mail : alex.michotte@az.vub.ac.be.