

## Diabetic ketoacidosis presenting as a cerebral venous sinus thrombosis

Kristel DE KEYZER<sup>1</sup>, Koen PAEMELEIRE<sup>1</sup>, Matti DE CLERCK<sup>2</sup>, Dirk PEETERS<sup>2</sup> and Jacques L. DE REUCK<sup>1</sup>

<sup>1</sup>Department of Neurology, Ghent University Hospital, Ghent and <sup>2</sup>Department of Neurology, AZ Groeninge, Kortrijk, Belgium

### Abstract

*Cerebral venous sinus thrombosis is an uncommon condition with a variable clinical presentation, often resulting in a delayed diagnosis. The most common risk factors are pregnancy and puerperium, oral contraceptive use, head injury, dehydration, blood dyscrasias, malignancies, and systemic diseases. We present a nineteen-year-old female in whom a superior sagittal sinus thrombosis was caused by dehydration during diabetic ketoacidosis and led to the diagnosis of new-onset type 1 diabetes mellitus. To our knowledge this is the first published report of a cerebral venous sinus thrombosis in association with diabetic ketoacidosis in an adult.*

**Key words :** Cerebral venous sinus thrombosis ; superior sagittal sinus thrombosis ; type 1 diabetes mellitus ; diabetic ketoacidosis ; dehydration ; headache.

### Introduction

Cerebral venous sinus thrombosis (CVST) is an uncommon condition with a variable clinical presentation and numerous risk factors. We present a case of superior sagittal sinus thrombosis caused by dehydration during diabetic ketoacidosis as the first presentation of type 1 diabetes mellitus. To our knowledge this is the first report of a CVST in association with diabetic ketoacidosis in an adult.

### Case report

A nineteen-year-old female, presenting with a severe throbbing bitemporal headache associated with nausea, vomiting, photophobia, dizziness, and general malaise, was admitted to the local hospital and soon afterwards transferred to the Ghent University Hospital. The present history had started two days before admission with a mild holocranial headache that had gradually worsened. Two days prior, the patient had had a mild skull trauma due to a fall on a winter sports holiday. She occasionally smoked cigarettes (< 10 cigarettes a month) and used an oral contraceptive containing 0.02 mg of ethinylestradiol and 0.075 mg of gestodene. The past history only revealed a cerebral concussion several years before.

On admission the patient seemed very anxious and mildly bradypneic. She had a moderately raised blood pressure (150/90 mmHg) and a slightly painful cervical mobilisation. Both the general and the neurological clinical examination were otherwise unremarkable. An urgent X-ray of the cervical spine and a non-contrast enhanced cerebral computerised tomography (CT) scan showed no evidence of posttraumatic lesions.

Over the next two days she became increasingly anxious and confused, evolving into a psychotic state. During that period she also gradually developed dysphasia, left abducens palsy, right inferior facial palsy, and bilateral fluctuating muscular weakness, predominating in the legs, leading to a tetraparesis with brisk tendon reflexes, foot cloni and Babinski's signs.

Laboratory studies showed mild haemoconcentration (haematocrit 49.9%, haemoglobin 17.3 g/dl), raised white cell count ( $12.9 \times 10^9/l$ ), normal platelet count, normal electrolytes, normal renal and liver function parameters, raised alpha-amylase (172 U/l) and lipase (241 U/l), very high serum glucose (3.38 g/l), raised C-reactive protein (10.3 mg/dl), raised triglycerides (157 mg/dl), raised total serum-cholesterol (224 mg/dl), raised lipoprotein(a) (72.90 mg/dl), raised D-dimer levels (2071 ng/ml), and metabolic acidosis (pH 7.25, pCO<sub>2</sub> 24.0 mmHg, pO<sub>2</sub> 110.2 mmHg, bicarbonate 10.3 mmol/l, base excess -15.0 mmol/l). Urine analysis demonstrated severe glucosuria (10.05 g/l) and severe ketonuria. Rehydration therapy and subcutaneous injections of soluble insulin were started.

An electroencephalogram (EEG) showed diffuse slow brain activity on a background of alpha activity. A follow-up CT brain scan and a magnetic resonance imaging (MRI) scan of the cervical spine revealed no abnormalities. Brain MRI showed bilateral cortical and subcortical ischaemic changes in the frontoparietal regions and in the occipital lobes (Fig. 1 A, B). MR venography (MRV) revealed a thrombosis of the superior sagittal sinus (Fig. 2). A treatment with intravenous heparin was subsequently started and the intake of oral contraceptives was interrupted.

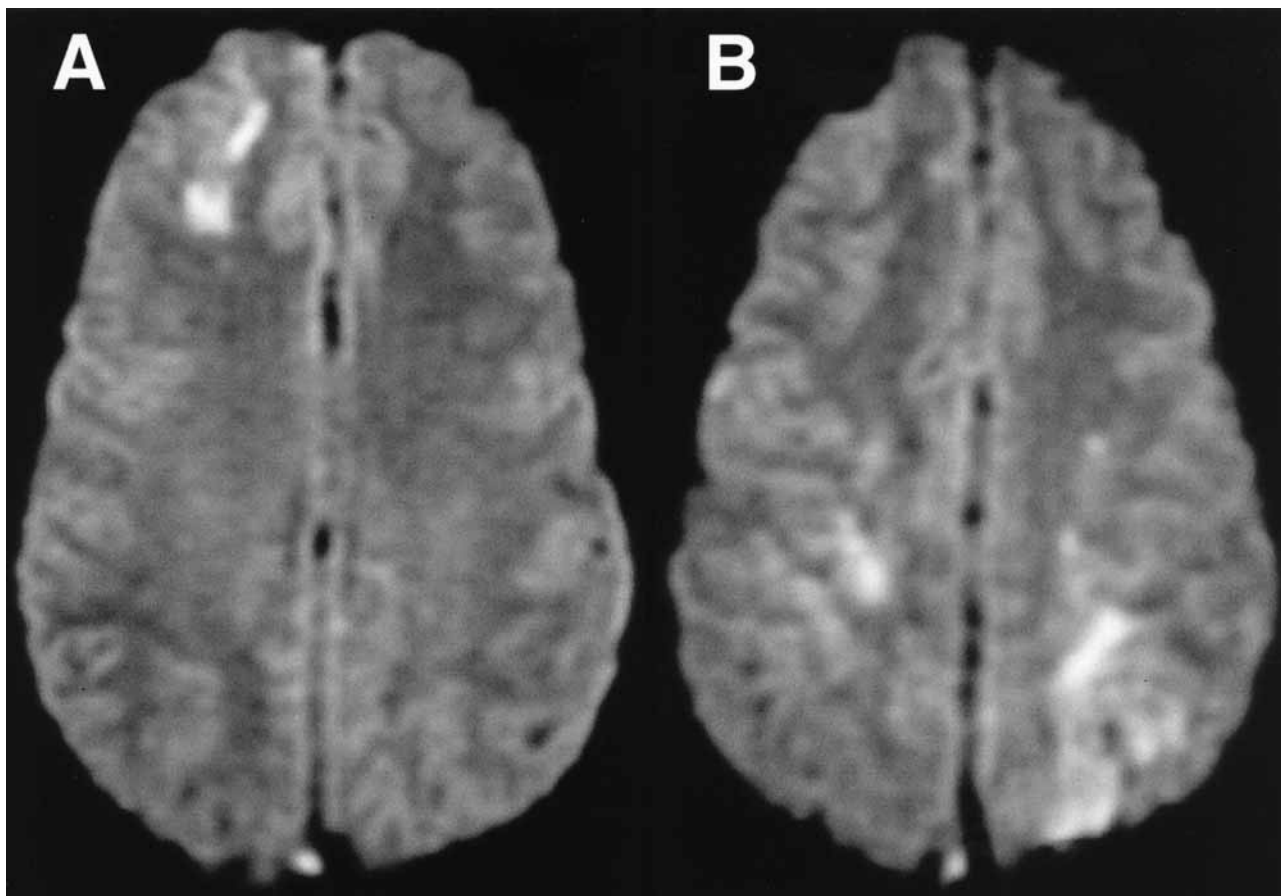


FIG. 1A and 1B. — Diffusion weighted images of horizontal sections at the upper level of the corpus callosum (A) and above (B) show increased signals in the right frontal subcortical region (A) and in both occipital lobes (B).

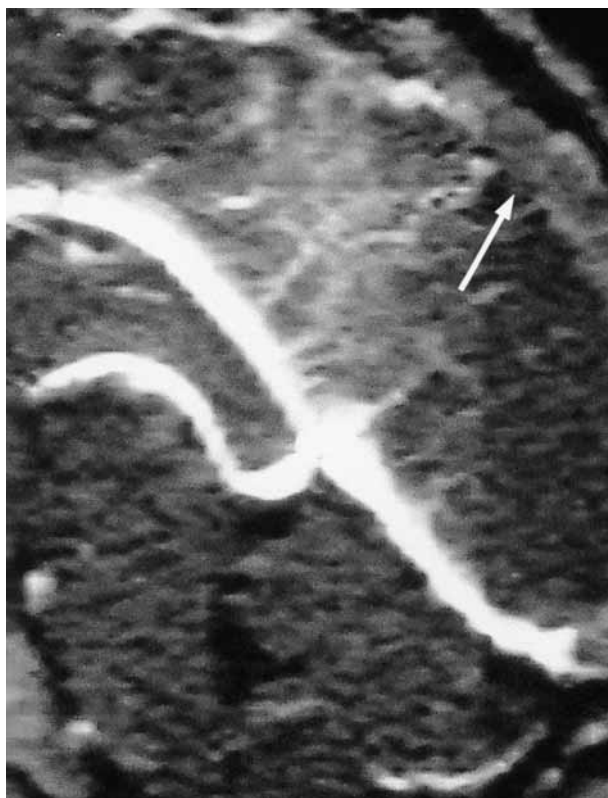

FIG. 2. — Sagittal reconstruction of the cerebral MR venography showing the occlusion of the superior sagittal sinus (arrow) contrasting with the patent deep venous system.

Screening for coagulopathies and auto-immune disorders showed normal antithrombin, normal protein C, normal protein S, normal activated protein C resistance, normal complement C3 and C4, normal homocystein, and absence of lupus anticoagulant, anticardiolipin antibodies and antinuclear antibodies.

Further history taking revealed that the patient had been experiencing polydipsia and polyuria for several weeks. She had also lost weight at a rate of 5 kg a month. Additional laboratory studies revealed a seriously elevated haemoglobin A1c (9.8%), normal C-peptide levels, absence of insulin auto-antibodies, and positive glutamic acid decarboxylase antibodies and islet cell antibodies, thus confirming the diagnosis of type 1 diabetes mellitus. A chronic treatment with subcutaneous soluble insulin and isophane insulin injections was started. The intravenous heparin therapy was continued for about 1 week, after which a treatment with acetylsalicylic acid in a dose of 160 mg daily was started.

The patient recovered well and clinical examination two weeks after admission merely revealed a remaining partial left abducens paresis with diplopia. During the following weeks the patient experienced several attacks of migraine with aura and several episodes of mild bitemporal headache. Two

months after admission the diplopia and the headaches had almost completely disappeared.

### Discussion

CVST is an uncommon condition that can present with a wide spectrum of clinical symptoms and signs, making it a difficult and often delayed diagnosis (Bousser *et al.*, 1985 ; McLean, 1991 ; Ameri and Bousser, 1992 ; Bousser, 2000 ; Connor and Jarosz, 2002 ; Ferro, 2002 ; Kimber, 2002).

Predisposing factors can be identified in 65-80% of patients (Ameri and Bousser, 1992 ; Martinelli *et al.*, 1998 ; Reuner *et al.*, 1998 ; Bousser, 2000 ; Connor and Jarosz, 2002 ; Kimber, 2002 ; Stam, 2003), with often more than one factor found in an individual patient (Bousser, 2000 ; Ferro, 2002). Among the more than 100 known factors associated with CVST are intracranial and regional infection, sepsis and systemic infection, intracranial space occupying lesions, head injury, pregnancy and puerperium, oral contraceptive use, malignancies, polycythaemia, anaemia, thrombocythaemia, coagulopathies, severe dehydration, Behcet's disease, inflammatory bowel disease, connective tissue diseases, sarcoidosis, nephrotic syndrome, and drugs (Bousser *et al.*, 1985 ; McLean, 1991 ; Ameri and Bousser, 1992 ; Martinelli *et al.*, 1998 ; Reuner *et al.*, 1998 ; Bousser, 2000 ; Connor and Jarosz, 2002 ; Ferro, 2002 ; Kimber, 2002 ; Stam, 2003).

In our patient a combination of several risk factors was found : recent head trauma, use of an oral contraceptive, and dehydration. However, since the head injury had been mild, without signs of a cerebral concussion, this factor was not thought to be significant. The intake of oral contraceptives is a well-known factor associated with CVST, although it rarely is the only etiological factor (Bousser *et al.*, 1985 ; McLean, 1991 ; Ameri and Bousser, 1992 ; Martinelli *et al.*, 1998 ; Reuner *et al.*, 1998 ; Connor and Jarosz, 2002 ; Ferro, 2002 ; Kimber, 2002 ; Stam, 2003). In this case the CVST was most likely triggered by the severe dehydration caused by diabetic ketoacidosis, while the intake of an oral contraceptive may have been an additional risk factor.

Our patient was screened for inherited and acquired prothrombotic conditions, including antithrombin deficiency, protein C deficiency, protein S deficiency, hyperhomocystinemia, and antiphospholipid antibodies (Bousser *et al.*, 1985 ; McLean, 1991 ; Ameri and Bousser, 1992 ; Martinelli *et al.*, 1998 ; Reuner *et al.*, 1998 ; Bousser, 2000 ; Connor and Jarosz, 2002 ; Ferro, 2002 ; Kimber, 2002 ; Stam, 2003). The presence of the G20210→A mutation in the prothrombin gene and the G1691→A factor V Leiden mutation, both associated with an increased risk of CVST (Martinelli *et al.*, 1998 ; Reuner *et al.*, 1998 ; Ferro, 2002 ; Kimber, 2002 ; Stam, 2003), was not tested,

and can therefore not be totally excluded as additional predisposing factors.

Severe dehydration is a well-known cause of CVST. However, only three other cases of CVST caused by dehydration during diabetic ketoacidosis have been reported in the literature, each time in a pediatric patient with known type 1 diabetes mellitus (Scibilia *et al.*, 1986 ; Keane *et al.*, 2002). A CVST in association with diabetic ketoacidosis in an adult has not previously been reported. To our knowledge this is the first published case of an adult patient in whom a CVST was the presenting syndrome leading to the diagnosis of a new-onset type 1 diabetes mellitus.

Neurological deterioration during an episode of diabetic ketoacidosis is usually caused by cerebral oedema, with only 10% of acute neurological episodes as a result of other causes (Rosenbloom, 1990 ; Keane *et al.*, 2002). Often no neuroimaging is performed in those cases such that the diagnosis of CVST might be missed and the appropriate treatment will not be given (Keane *et al.*, 2002). When a patient with diabetic ketoacidosis develops neurological signs and symptoms, it is important to explore the possibility of a CVST.

### Acknowledgement

We wish to thank Prof. Dr. Em. Marc Kunnen for processing the images for publication.

### REFERENCES

- AMERI A., BOUSSER M. G. Cerebral venous thrombosis. *Neurol. Clin.*, 1992, **10** : 87-111.
- BOUSSER M. G. Cerebral venous thrombosis : diagnosis and management. *J. Neurol.*, 2000, **247** : 252-258.
- BOUSSER M. G., CHIRAS J., BORIES J., CASTAIGNE P. Cerebral venous thrombosis – a review of 38 cases. *Stroke*, 1985, **16** : 199-213.
- CONNOR S. E., JAROSZ J. M. Magnetic resonance imaging of cerebral venous sinus thrombosis. *Clin. Radiol.*, 2002, **57** : 449-461.
- FERRO J. M. Cerebral venous thrombosis. *J. Neuro-radiol.*, 2002, **29** : 231-239.
- KEANE S., GALLAGHER A., ACKROYD S., MCSHANE M. A., EDGE J. A. Cerebral venous thrombosis during diabetic ketoacidosis. *Arch. Dis. Child.*, 2002, **86** : 204-205.
- KIMBER J. Cerebral venous sinus thrombosis. *Q. J. Med.*, 2002, **95** : 137-142.
- MARTINELLI I., SACCHI E., LANDI G., TAIOLI E., DUCA F., MANNUCCI P. M. High risk of cerebral-vein thrombosis in carriers of a prothrombin-gene mutation and in users of oral contraceptives. *N. Engl. J. Med.*, 1998, **338** : 1793-1797.
- MCLEAN B. N. Dural sinus thrombosis. *Br. J. Hosp. Med.*, 1991, **45** : 226-231.
- REUNER K. H., RUF A., GRAU A., RICKMANN H., STOLZ E., JÜTLER E., DRUSCHKY K.-F., PATSCHEKE H. Prothrombin gene G<sub>20210</sub>→A transition is a risk factor for cerebral venous thrombosis. *Stroke*, 1998, **29** : 1765-1769.

- ROSENBLOOM A. L. Intracerebral crises during treatment of diabetic ketoacidosis. *Diabetes Care*, 1990, **13** : 22-33.
- SCIBILIA J., FINEGOLD D., DORMAN J., BECKER D., DRASH A. Why do children with diabetes die? *Acta Endocrinol. Suppl.*, 1986, **279** : 326-333.
- STAM J. Cerebral venous and sinus thrombosis : incidence and causes. *Adv. Neurol.*, 2003, **92** : 225-232.

Prof. Dr. J. DE REUCK,  
Department of Neurology,  
Ghent University Hospital,  
De Pintelaan 185,  
B-9000 Ghent (Belgium).  
E-mail : jacques.dereuck@yucom.be.