

## Case reports

### Could visual neglect induce amblyopia ?

J.-C. BIER<sup>1</sup>, M. VOKAER<sup>1</sup>, P. FERY<sup>2</sup>, J. GARBUSINSKI<sup>1</sup>, G. VAN CAMPENHOUDT<sup>3</sup>, S. A. BLECIC<sup>1</sup> and E. J. BARTHOLOMÉ<sup>1</sup>

<sup>1</sup>Department of Neurology, <sup>2</sup>Department of Neuropsychology & <sup>3</sup>Department of Occupational Therapy, Erasme Hospital, Université Libre de Bruxelles, Brussels, Belgium

#### Abstract

*Oculomotor nerve disease is a common cause of diplopia. When strabismus is present, absence of diplopia has to induce the research of either uncovering of visual fields or monocular suppression, amblyopia or blindness. We describe the case of a 41-year-old woman presenting with right oculomotor paresis and left object-centred visual neglect due to a right fronto-parietal haemorrhage expanding to the right peri-mesencephalic cisterna caused by the rupture of a right middle cerebral artery aneurysm. She never complained of diplopia despite binocular vision and progressive recovery of strabismus, excluding uncovering of visual fields. Since all other causes were excluded in this case, we hypothesise that the absence of diplopia was due to the object-centred visual neglect. Partial internal right oculomotor paresis causes an ocular deviation in abduction ; the image being perceived deviated contralaterally to the left. Thus, in our case, the neglect of the left image is equivalent to a right monocular functional blindness. However, bell cancellation test clearly worsened when assessed in left monocular vision confirming that eye patching can worsen attentional visual neglect. In conclusion, our case argues for the possibility of a functional monocular blindness induced by visual neglect. We think that in presence of strabismus, absence of diplopia should induce the search for hemispatial visual neglect when supratentorial lesions are suspected.*

**Key words :** Monocular ; blindness ; neglect.

#### Introduction

Hemispatial visual neglect (HVN) is defined as a defect of perception, attention, representation, and/or performing actions in the area contralateral to a cerebral lesion despite normal motor and perception function<sup>9</sup>. HVN is a complex phenomenon that can be divided into different nosological entities, which may be isolated or associated. This neurological deficit may be predominantly motor (intentional) or perceptual (attentional) (12), object-centred or scene-based, externalised or internalised (5). The commonly reported brain area most associated with neglect is the right posterior parietal lobe, especially around the temporoparietal

junction. A recent study identified the inferior parietal lobe, lying just beneath the cortical surface of the rostroventral angular gyrus, as the area most commonly involved in lesions producing HVN (8). No therapy has proven long term efficacy in HVN. Right eye patching has been reported to reduce neglect in some patients with right hemisphere damage (3, 4, 10, 11) but also to worsen attentional neglect (2). We describe the case of a patient presenting a left object-centred HVN associated with right exotropia due to oculomotor paresis who never complained of diplopia. Since all other causes were excluded in this case, we hypothesise that the absence of diplopia was due to the object-centred HVN. Noteworthy, HVN significantly worsened when assessed in left monocular vision.

#### Case report

A 41-year-old right-handed woman presented with rapidly increasing subacute headache followed by vomiting episodes and loss of consciousness. Cerebral computed tomography showed an intraparenchymatous and subarachnoidal right fronto-parietal haemorrhage. A right middle cerebral artery aneurysm was found on arteriography and clipped the same day. Seven days later, cerebral magnetic resonance imaging showed an expansion of the haemorrhage to the right perimesencephalic cisterna. Moreover, a right ischaemic fronto-parietal stroke and another haemorrhage at the head of the right caudate nucleus appeared (Fig. 1). At that time, arteriography showed multiple vasospasms on the right internal carotid from the beginning of the ophthalmic artery up to the middle cerebral artery. Medical history of this commercial secretary consisted of hypertension treated by hydrochlorothiazide 25 mg/day and triamterene 50 mg/day since 1999 and a multinodular goitre. When admitted in our rehabilitation department one week later, clinical examination was normal except for the goitre, the craniotomy scar and a stiffness of the neck. Neurological examination disclosed a right internal oculomotor paresis, with eyelid ptosis and reflectic mydriasis.

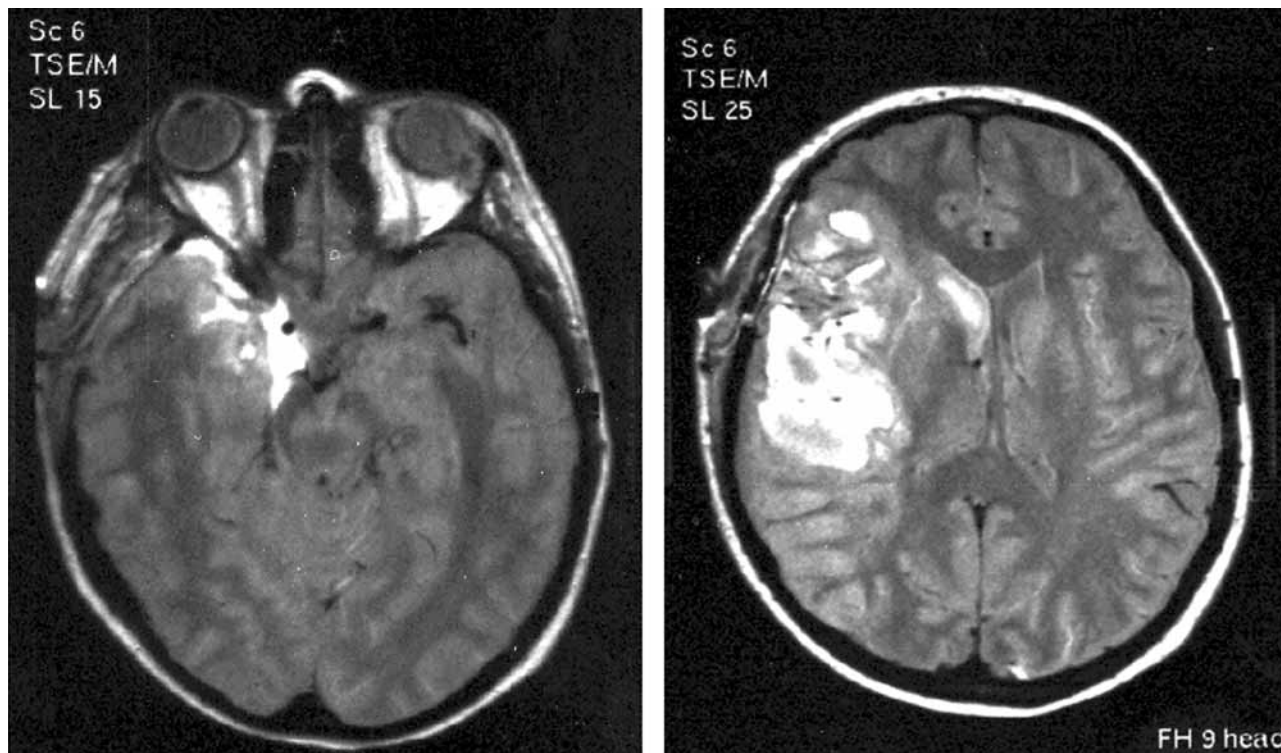


FIG. 1. — Cerebral MRI performed seven days after onset. A : Axial slice showing the haemorrhage as a T2-hyperintense signal expanding to the perimesencephalic cisterna. B : Axial slice showing the infarct as an extensive T2-hyperintense signal in the right frontoparietal lobes and the haemorrhage at the head of the right caudate nucleus.

Although she was daily asked about it, the patient never complained of diplopia despite progressive recovery of the strabismus. However, she frequently closed her right eye while being unable to explain why. Right exotropia was confirmed by Lancaster test. Visual acuity was normal for both eyes (10/10) and Bagolini striated lens test revealed a normal binocular vision without monocular suppression. Other abnormalities observed were a left inferior facial paresis (4/5) of the upper and lower limbs, a left Babinski sign and a left multimodal hemihypoesthesia. Complete neuropsychological testing did not reveal memory impairment or language disturbances. This examination included evaluation of time and space orientation, digit span (forwards = 5, there was no backward digit span), Buschke selective reminding task (15/15 on delayed recall score, 20 minutes after the learning phase) and informal investigation of verbal expression and comprehension. The Bachy-Langedock (1) test which is a confrontation naming task using line-drawings (90 items) was mildly impaired (84/90) ; Errors on the Bachy-Langedock were only word finding problems. At no time did she had troubles with picture identification. There was no impairment of executive functions as assessed by the Winconsin Card Sorting Test, Stroop test and verbal fluency (“p”, “r” & fruits). Visual spatial abilities were assessed with the Rey complex figure (< percentile 10, with all mistakes done on the left-side) and La Ruche<sup>13</sup> which is a

visual-spatial learning task, the patient was presented with a kind of symmetric matrix comprising 45 squares. Ten of those squares were filled with black colour. There were 5 learning trials. On each trial, the matrix was presented to the patient for 45 seconds and she had to learn the location of the ten black squares. She was then given an empty matrix and had to cross the squares corresponding to the black ones on the model. On the model, there were 2 black squares on the midline, 4 on the left side, and 4 on the right side. On all 5 trials, the patient only crossed correctly 3 squares on the left side against 6 squares on the right. Moreover, there were 17 responses on the right side against 10 responses on the left. Description of complex visual scenes was impaired for the left elements but she was able to read sentences or isolated and dispersed words on a paper. Simple cancellation tasks (circles and lines ; figure 2A and 2B) were normal. However, addition of distracters (bell cancellation test (6)) revealed the left HVN (figure 3 ; 19/34). On a line bisection task, during which the patient is asked to bisect the middle of various lines randomly disposed on a paper, there was a mean right deviation of five percent but no forgotten line. A drawing copy task of five objects horizontally disposed, confirmed the presence of a left object-centred HVN. Distance had no effect on the expression of her HVN or on the absence of complain of diplopia. Interestingly, on bell cancellation test, HVN significantly worsened when assessed in left




FIG. 2. — *Hemispatial visual spatial neglect*. A : There was no omission on circle cancellation test. B : There was no omission on line cancellation test.




FIG. 3. — Bell cancellation test performed in binocular vision revealing a left visual spatial neglect (15 bells were forgotten on the left side).

monocular vision (8 bisected items on 34) compared to right monocular vision (17/34 ; Fisher test exact p value = 0.0432) or binocular vision (19/34 ; p = 0.0125). This was not due to a learning effect, the performance worsening during tests achievement. Eyes patching had no effect on her behaviour, except for a movement of the neck and the face in case of left patch to put the right eye in the axis of her vision.

### Discussion

Despite exotropia due to oculomotor paresis, our patient never presented diplopia. Usual causes of absence of diplopia in presence of strabismus were excluded. Monocular suppression was excluded by a normal binocular vision on Bagolini striated lens test. Visual acuity was normal for both eyes. Uncovering of visual fields could have explained the absence of diplopia when exotropia angle was maximal. However, absence of diplopia persisted during recovery even when exotropia angle was clearly too low to induce uncovering of visual fields. Moreover, the fact that the patient frequently closed the right eye argues for an unconscious perception of two images and so for a covering of her visual fields. This kind of unconscious perception has already been described in HVN (7). Indeed, patients presenting HVN were able to express feelings induced by visual information coming from the left side of a picture despite the absence of its conscious perception. In our case, neuropsychological examination disclosed the presence of an isolated left object-centred HVN due to the right intraparenchymatous frontoparietal haemorrhage. This localisation is in concordance with the recently reported anatomy of HVN (8). Since other causes of absence of diplopia were excluded in this case, we hypothesise that it was due to the object-centred visual neglect. Partial internal right oculomotor paresis causes an ocular deviation in abduction, the image being perceived deviated contralaterally to the left. Thus, in our case, the neglect of the left image is equivalent to a right monocular functional blindness.

Noteworthy, the bell cancellation test was significantly worse when performed in left monocular vision than it was in right or binocular vision. Dissociation between this increasing of HVN when patching the right eye and the right functional blindness may first seem contradictory. Increased neglect in left monocular vision has already been described in a case of left predominantly attentional rather than motor HVN (2). Unfortunately, search for motor neglect in our patient was not performed as a consequence of her recovery. The object-centred feature of the HVN and the unconscious perception of the splitting in two images argue for its attentional predominance. Whatever, our case confirms that eye patching may worsen HVN (2).

In conclusion, our case argues for the possibility of a functional monocular blindness induced by visual neglect. We think that in presence of strabismus, absence of diplopia should induce the search for HVN when supratentorial lesions are suspected.

### REFERENCES

- BACHY-LANGEDOCK M. N. Batterie d'examen des troubles en dénomination. Bruxelles : Editest, 1989.
- BARRETT A. M., CRUCIAN G. P., BEVERSDORF D. Q., HEILMAN K. M. Monocular patching may worsen sensory-attentional neglect : a case report. *Arch. Phys. Med. Rehabil.*, 2001, **82** : 516-518.
- BUTTER C. M., KIRSCH N. L., REEVES G. The effect of lateralized dynamic stimuli on unilateral spatial neglect following right hemisphere lesions. *Restorative Neurol. Neurosci.*, 1990, **2** : 39-46.
- BUTTER C. M., KIRSCH N. L. Combined and separate effects of eye patching and visual stimulation on unilateral neglect following stroke. *Arch. Phys. Med. Rehabil.*, 1992, **73** : 1133-1139.
- GAINOTTI G. L'héminégligence. *La recherche*, 1987, **18** : 476-483.
- GAUTHIER L., DEHAUT F., JOANETT J. The Bell test : A quantitative and qualitative test for visual neglect. *Int. J. Clin. Neuropsychol.*, 1989, **11** : 49-54.
- MARSHALL JOHN C., HALLIGAN PETER W. Blindsight and insight in visuo-spatial neglect. *Nature*, 1988, **336** : 766-767.
- MORT D. J., MALHOTRA P., MANNAN S. K., RORDEN C., PAMBAKIAN A., KENNARD C., HUSAIN M. The anatomy of visual neglect. *Brain*, 2003, **126** : 1986-1997.
- ROSETTI Y., RODE G., PISELLA L., FARNÉ A., LI L., BOISSON D., PERENIN M. T. Prism adaptation to rightward optical deviation rehabilitates left hemispatial neglect. *Nature*, 1998, **395** : 166-169.
- SERFATY C., SOROKER N., GLICKSOHN J., MYSLOBODSKY M. S. Does monocular viewing improve target detection in hemispatial neglect ? *Restorative Neurol. Neurosci.*, 1995, **9** : 77-83.
- SOROKER N., COHEN T., BARATZ C., GLICKSOHN J., MYSLOBODSKY M. S. Is there a place for ipsilesional eye patching in neglect rehabilitation ? *Behav. Neurol.*, 1994, **7** : 159-164.
- TEGNÉR R., LEVANDER M. Through a looking glass. A new technique to demonstrate directional hypokinesia in unilateral neglect. *Brain*, 1991, **114** : 1943-1991.
- VIOLON A., WIJNS CH. (1984). La Ruche : Test de perception et d'apprentissage progressif en mémoire visuelle. Belgique : Edition de l'Application des Techniques Modernes.

J.-Chr. BIER,  
Hôpital Erasme,  
Service de Neurologie (3<sup>ème</sup> étage),  
Route de Lennik 808,  
B-1070 Bruxelles (Belgique).  
E-mail : Jean-Christophe.Bier@ulb.ac.be.