

## Carotid thrombus formation and extension during anticoagulation : a case report of large vessel disease and hypercoagulable state in systemic sclerosis

Dimitri RENARD and Chérif HEROUM

Department of Neurology, Hôpital Gui de Chauviac, CHU Montpellier, Montpellier, France

### Abstract

*Systemic sclerosis (SSc) is an autoimmune multisystem disorder of connective tissue characterized by widespread vascular lesions and fibrosis. Limited cutaneous systemic sclerosis (lcSSc) and diffuse cutaneous systemic sclerosis (dsSSc) are both subsets of SSc. The vascular component of SSc is an important part of the disease. Especially Raynaud's phenomenon and microcirculatory abnormalities are well recognized. Enhanced coagulation pathways, decreased fibrinolysis, and endothelial dysfunction probably contribute to vascular events in SSc. Macrovascular disease is not recognized as a major feature of SSc. However, several studies report an increase in large vessel disease and mortality rate attributable to cardiovascular causes.*

*We present a patient with lcSSc with an acute embolic stroke due to a large carotid thrombus. A hypercoagulable state was suspected because of thrombus formation during oral anticoagulation and extension during intravenous heparin treatment. This is one of the few reports of large vessel disease in systemic sclerosis. The hypercoagulable state may be related to systemic sclerosis.*

**Key words :** Systemic sclerosis ; hypercoagulable state ; anticoagulation ; carotid thrombus.

### Case report

A 67-year old woman with limited cutaneous systemic sclerosis (lcSSc) presented with sudden onset left hemiplegia and hemianesthesia. At the age of 48, twenty-four years after the onset of Raynaud's phenomenon, the diagnosis of lcSSc was made when digital ulceration and skin sclerosis (limited to fingers and hands) occurred, in presence of anti-centromere antibodies. Oesophageal dysmotility occurred a few years later, and pulmonary hypertension was diagnosed six months before admission. The rest of her past medical history was significant for arterial hypertension, past smoking, and acute myocardial infarction. On admission, her medication consisted of oral anticoagulation in treatment for pulmonary hypertension. No other treatment was given for lcSSc. MRI showed a lesion of restricted diffusion on Apparent

Diffusion Coefficient (ADC) sequences within the right middle cerebral artery distribution, confirming acute ischaemic stroke. CT angiography revealed a large mobile thrombus in the right internal carotid artery overlying an atheromatous plaque (Fig. 1A, B). Blood count, CRP and renal function were normal. International Normalized Ratio (INR) on admission was 2.1 (reference value for untreated patient is 1.0). Oral anticoagulation was stopped and intravenous unfractionated heparin treatment was started. One week later, transient clinical deterioration of left hemiplegia occurred. Activated partial thromboplastin time (aPTT) at that moment was 67.5 seconds (reference value is inferior to 34 seconds) and platelet count was normal. MRI was unchanged. CT angiography showed an extension of the thrombus (Fig. 1C, D). Surgical thrombectomy and carotid endarterectomy were performed. No other ischaemic event occurred. Thoracic, abdominal, and pelvic CT scan showed no abnormalities. Levels of anticardiolipin and beta2-glycoprotein I antibodies were normal.

Although direct association of carotid artery disease and SSc in this patient can not be proven, a hypercoagulable state is strongly suspected because of thrombus formation during oral anticoagulation, and thrombus extension during intravenous heparin treatment.

### Discussion

SSc is an autoimmune multisystem disorder of connective tissue characterized by widespread vascular lesions and fibrosis that affects the skin and various internal organs. Etiology is unknown. Vascular injury is the basis for the major clinical manifestations of SSc including pulmonary hypertension, myocardial dysfunction, and renal involvement. Progressive vasculopathy most commonly involves the microvascular system. Intimal proliferation, medial thinning, adventitial fibrosis, and thickening of the basement membrane eventually lead to vessel obliteration. Vasomotor disturbances, endothelial cell dysfunction, increased vascular

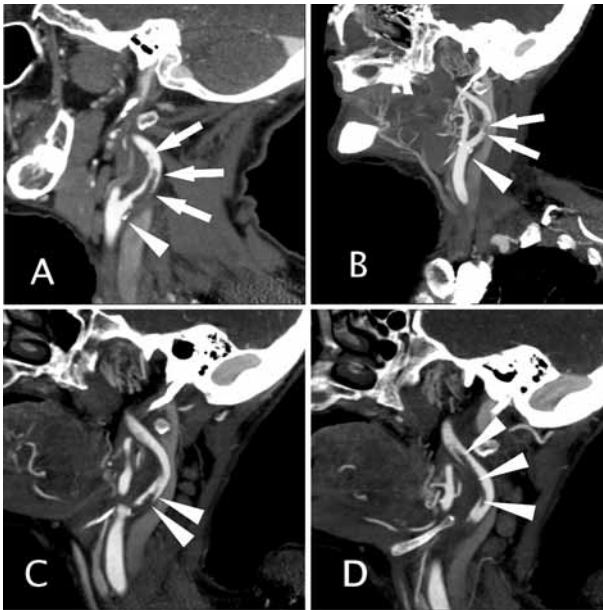


FIG. 1. — (A, B) CT angiography showing a 3 cm large mobile thrombus (arrows) in the right internal carotid artery overlying a partly calcified atheromatous plaque (arrowhead). (C, D) Control CT angiography showing an extension of the thrombus to 7 cm (arrowheads).

wall thickness, enhanced coagulation pathways, decreased fibrinolysis, and increased adhesiveness of the blood vessels to platelets and lymphocytes may all contribute to vascular events in SSc (1-6). The mechanism of endothelial injury in SSc is still elusive, yet endothelial apoptosis mediated by antiendothelial antibodies is the most attractive hypothesis. The extent of injury and dysfunction is reflected by changes in the circulating levels of vascular markers. The increased release of endothelin, thromboxane, factor VIII antigen, von Willebrand factor and thrombomodulin are signs of such injury to endothelial cells. The initial triggers for the vascular pathology are not known.

In SSc patients, high plasma levels of fibrinogen, endothelin, anticardiolipin and beta2-glycoprotein I antibodies, lipoprotein(a) [Lp(a)], homocysteine, prothrombin fragment 1 + 2, tissue plasminogen activator inhibitor, beta-thromboglobulin (a platelet-derived protein), platelet factor 4, thrombin-antithrombin III complex (a sensitive marker for activation of intravascular coagulation), and antithrombin III, together with a defective tissue plasminogen activator release can be found. These data are indicative of increased thrombin generation and fibrin production, and a depressed fibrinolytic activity, which might predispose these patients to thrombotic complications. These coagulation abnormalities may be related to the pathophysiology of SSc, not only as a result of chronic vessel wall damage, but as an active intravascular amplification system which may contribute to the progression of micro- and macrovascular disease. Lp(a) is a low-density lipoprotein particle bound to

apolipoprotein (a) that represents a risk factor of atherosclerosis. Increased levels of Lp(a) may play a role in the macrovascular involvement in SSc. Plasma levels of factor VIII related antigen in SSc patients treated with factor XIII were significantly lower than those of untreated SSc patients, supporting the hypothesis that factor XIII plays an improving role on endothelial damage. The presence of most of the described plasma abnormalities seems to be correlated to disease severity of SSc and the presence of pulmonary hypertension. The impact of vascular pathology on the evolution of tissue fibrosis is not known. Cytokines (transforming growth factor beta, interleukin-4), vascular factors (endothelin), and growth factors (platelet derived growth factor, connective tissue growth factor) are possibly crucial signals that link the vascular disease to tissue fibrosis.

Although macrovascular disease is not recognized as a major feature of SSc, increased prevalence of large vessel disease and mortality rate attributable to cardiovascular causes has been described (7-10). The presence of asymptomatic macrovascular disease, in the form of more frequent as well as more severe carotid artery disease and peripheral arterial obstructive disease (PAOD), can be identified by non-invasive vascular assessments (carotid duplex scanning, measurement of ankle brachial blood pressure index, and Edinburgh Claudication questionnaire). Therefore, SSc patients may have an increased risk of stroke. There are similarities in clinical symptomatology and histopathology between SSc and atherosclerotic disease. However, it is unclear if macrovascular disease in SSc is only due to atherosclerosis, or if other mechanisms that play a role in the microvascular involvement are also concerned in macrovessel disease in SSc patients.

#### REFERENCES

1. AMES P. R., LUPOLI S., ALVES J., ATSUMI T., EDWARDS C. *et al.* The coagulation/fibrinolysis balance in systemic sclerosis: evidence for a haematologic stress syndrome. *Br. J. Rheumatol.*, 1997, **36**: 1045-1050.
2. MAEDA M., KACHI H., MORI S. Plasma levels of molecular markers of blood coagulation and fibrinolysis in progressive systemic sclerosis (PSS). *J. Dermatol. Sci.*, 1996, **11**: 223-227.
3. PICILLO U., MIGLIARESI S., MARCIALIS M. R., FERRUZZI A. M., TIRRI G. Clinical setting of patients with systemic sclerosis by serum autoantibodies. *Clin. Rheumatol.*, 1997, **16**: 378-383.
4. LOTTI T., CERINIC M. M., MARMUGI D., FABBRI P. Cutaneous fibrinolytic activity in scleroderma. *Clin. Exp. Rheumatol.*, 1985, **3**: 249-253.
5. MARZANO A. V., FEDERICI A. B., GASPARINI G., MANNUCCI P. M., CAPUTO R. *et al.* Coagulation factor XIII, endothelial damage and systemic sclerosis. *Eur. J. Dermatol.*, 2000, **10**: 14-17.

6. CERINIC M. M., VALENTINI G., SORANO G. G., D'ANGELO S., CUOMO G. *et al.* Blood coagulation, fibrinolysis, and markers of endothelial dysfunction in systemic sclerosis. *Semin. Arthritis. Rheum.*, 2003, **32** : 285-295.
7. STAFFORD L., ENGLERT H., GOVER J., BERTOUCHE J. Distribution of macrovascular disease in scleroderma. *Ann. Rheum. Dis.*, 1998, **57** : 476-479.
8. CHENG K. S., TIWARI A., BOUTIN A., DENTON C. P., BLACK C. M. *et al.* Carotid and femoral arterial wall mechanics in scleroderma. *Rheumatology*, 2003, **42** : 1299-1305.
9. VEALE D. J., COLLIDGE T. A., BELCH J. J. Increased prevalence of symptomatic macrovascular disease in systemic sclerosis. *Ann. Rheum. Dis.*, 1995, **54** : 853-855.
10. BRYAN C., HOWARD Y., BRENNAN P., BLACK C., SILMAN A. Survival following the onset of scleroderma : results from a retrospective inception cohort study of the UK patient population. *Br. J. Rheumatol.*, 1996, **35** : 1122-1126.

Renard DIMITRI, M.D.,  
Department of Neurology,  
Hôpital Gui de Chauliac, CHU Montpellier,  
80 Avenue Augustin Fliche,  
34295 Montpellier (France).  
E-mail : dimitrirenard@hotmail.com.