

Hemiparkinsonism due to frontal meningioma

Dario BENINCASA, Andrea ROMANO, Luciano MASTRONARDI, Clelia PELLICANO,
Alessandro BOZZAO and Francesco E. PONTIERI

Department of Neuroscience, Sant' Andrea Hospital, II Faculty of Medicine, University 'La Sapienza, Rome, Italy

Abstract

We describe a case with right hemiparkinsonism due to a frontal meningioma with surrounding edema compressing the basal ganglia. The initial diagnosis of idiopathic Parkinson's disease (PD) was made in another institution on the basis of the positive family history, the clinical symptoms and the asymmetric reduction of striatal tracer binding in a single photon emission computed tomography study for the dopamine transporter. The symptoms of parkinsonism resolved completely shortly after surgery for removal of the tumor. This case points to the significance of structural neuroimaging in the evaluation of parkinsonism even in cases that fulfill all the necessary clinical criteria for idiopathic PD.

Key words : Meningioma ; parkinsonism ; brain MRI ; DAT-Scan.

Introduction

Parkinson's disease (PD) is a chronic progressive neurodegenerative disorder characterized by rest tremor, bradykinesia and rigidity (Hughes *et al.*, 2001). Symptoms usually start unilaterally and spread gradually to the other side of the body. A positive response to dopaminergic therapy is required to fulfill the criteria for the diagnosis of idiopathic PD. Although several hereditary forms of PD have been described (Bonifati *et al.*, 2004), the disease is essentially idiopathic. Epidemiological studies allowed the identification of several risk factors for sporadic PD, including the age, the exposure to neurotoxins and the positive family history (Sellbach *et al.*, 2006). The cardinal motor symptoms of PD depend upon progressive degeneration of the dopaminergic nigrostriatal neurons (Hughes *et al.*, 1992) ; such damage can be identified in vivo by functional neuroimaging techniques, such as positron emission tomography or single photon computed emission tomography (SPECT) (Antonini and De Notaris, 2004).

Accurate diagnosis of idiopathic PD continues to be challenging. Clinico-pathological studies found a 76% accuracy of clinical diagnosis of idiopathic PD (Hughes *et al.*, 1992). Using standardized

clinical criteria, the diagnostic accuracy increased to 90% (Hughes *et al.*, 2001). There is a variety of different causes of parkinsonism, including idiopathic PD, atypical parkinsonian syndromes, parkinsonism in hereditary degenerative diseases and secondary parkinsonism. These latter are caused by structural, toxic, metabolic or infectious mechanisms. Intracranial neoplasms represent a rare cause of secondary parkinsonism (Krauss *et al.*, 1995 ; Salvati *et al.*, 2000).

We report here the case of a patient with right hemiparkinsonism due to left frontal meningioma with surrounding edema. The tumor was identified several months after the onset of motor symptoms because of the delay in carrying out structural neuroimaging examinations.

Case report

I.M., a 61-year-old female with a strong family history of PD (the father, the mother and two uncles received the diagnosis of idiopathic PD), was originally referred to an out-patient service for Movement Disorder of another Institution in December, 2004, because of the occurrence of rest tremor and slowness of movements in the right upper limb during the last four months. The neurological examination showed initial right hemiparkinsonism, with rest tremor, bradykinesia and slight rigidity. There were no signs of sensory, pyramidal or cerebellar damage. Following the first neurological examination, the patient was submitted to SPECT study for the dopamine transporter (DAT-Scan), that showed a significant reduction of tracer binding at the level of the left striatum (Fig. 1a). On the basis of the positive family history, the neurological symptoms, and the results of the DAT-Scan examination, the patient was diagnosed as having idiopathic PD, and therapy with pramipexole (up to the dosage of 0.7 mg, t.i.d.) was initiated in February, 2005. Three months later, during an out-patient examination, the hemiparkinsonian symptoms were slightly reduced, but the patient complained distal limb edema, slowness of thinking, and sudden sleep attacks. Pramipexole was,

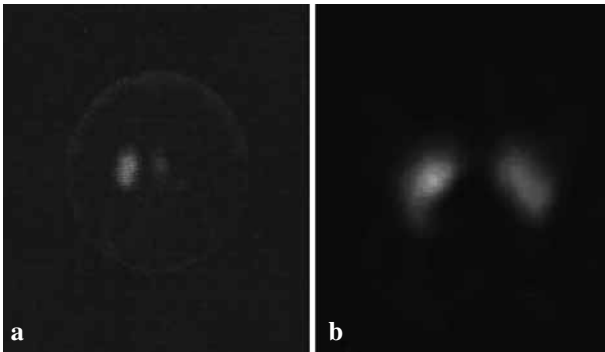


FIG. 1. — [^{123}I]fluopane SPECT (DAT-Scan) showing the asymmetrical tracer binding in the pre-operative scan (a) and the normalization of signal in the scan repeated 6 months after removal of the meningioma (b).

therefore, suspended, and levodopa/carbidopa was initiated and progressively increased up to 400 mg/100 mg per day.

In October, 2005, the patient referred to our out-patient service for Movement Disorders. At that time, the neurological examination showed an hemiparkinsonian syndrome with rest tremor, rigidity, and bradykinesia of the right limbs (more pronounced in the upper limb). Moreover, the patient complained frequent vomiting, left ear tinnitus, slowness of thinking, and repeated, transient episodes of right palpebral ptosis. The deep tendon reflexes were asymmetrical (slightly brisk in the right limbs), and the right plantar reflex was equivocal. There were no signs of sensory or cerebellar impairment. She had spontaneously reduced levodopa/carbidopa therapy to 100 mg/25 mg, t.i.d., since she interpreted those accessory symptoms as 'side-effects' of the antiparkinsonian therapy. The routine hematological and biochemical examination was normal.

Because of the poor response to antiparkinsonian drugs, the slight unilateral pyramidal signs and the

other accessory symptoms, the patient was submitted to gadolinium-enhanced brain MRI scan, that showed a large left frontal tumor, probably meningioma, with surrounding edema compressing the basal ganglia and the mesencephalon (Fig. 2a).

Antiparkinsonian drugs were discontinued before surgery. Surgical excision of the tumor was followed by a rapid improvement of the neurological symptoms. The hemiparkinsonian signs were completely resolved seven days after surgery. Pathology confirmed the diagnosis of meningioma (transitional variety). The postoperative MRI scan showed complete removal of the tumor (Fig. 2b), together with a region of hyperintensity on T2-weighted images of the subcortical white matter in the left hemisphere (Fig. 2c). Because of this lesion and of the EEGraphic evidence of sharp waves in the left frontoparietal hemisphere, antiepileptic therapy with phenobarbital (100 mg/day) was initiated. Six months after surgery (April, 2006) the patient was submitted to a second DAT-Scan examination, that showed almost complete recovery of the asymmetry of tracer binding (Fig. 1b). MRI scans, repeated 6, 12, 18, and 24 months after surgery, remained unmodified. On the last out-patient examination (November, 2007) the neurological exam was normal with the exception of an equivocal right plantar reflex response.

Discussion

The diagnosis of idiopathic PD is, at present, based mostly on the clinical findings. In typical cases, parkinsonian symptoms begin unilaterally and gradually worsen and spread to the opposite side of the body (Hughes *et al.*, 1992 ; Klockgether, 2004). Using the most recent clinical criteria, the occurrence of misdiagnoses has markedly reduced, but a 10% rate of diagnostic errors may still occur (Hughes *et al.*, 2001).

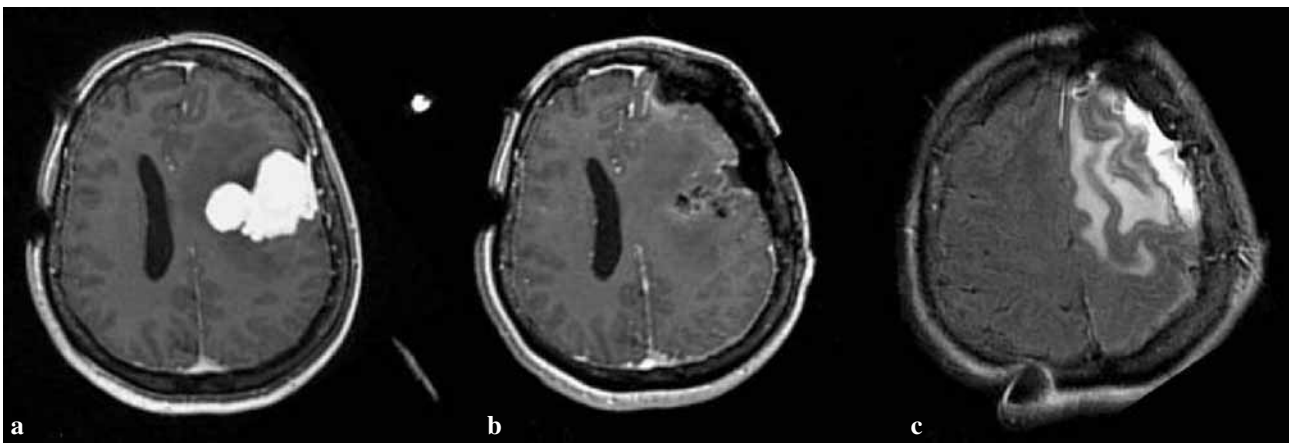


FIG. 2. — Pre-operative gadolinium-enhanced MRI showing a deep-reaching meningioma causing compression of the underlying hemisphere and ventricular system (a). Post-operative gadolinium-enhanced MRI showing complete removal of meningioma (b) and hyperintense signal of the subcortical white matter on T2 weighted images (c).

In the early stages, idiopathic PD should be distinguished from essential tremor, atypical parkinsonism, parkinsonism in hereditary diseases, and secondary parkinsonism (Hughes *et al.*, 1992). To this end, both functional and structural neuroimaging studies may help (Hughes *et al.*, 2001). Functional studies, such as DAT-Scan examination, allow the identification of asymmetric tracer binding in the striatum, in particular the reduction of tracer binding in the putamen contralateral to the parkinsonian symptoms in idiopathic PD, whereas such examination is normal in essential tremor (Benamer *et al.*, 2000 ; Antonini and De Notaris, 2004). DAT-Scan findings in secondary parkinsonism may, however, give equivocal results, because tracer binding may be influenced by structural lesions that damage the dopaminergic nigrostriatal pathway (Antonini and De Notaris, 2004). Structural neuroimaging techniques, and MRI in particular, are useful for the identification of brain lesions responsible of the parkinsonism even in cases that fulfill all necessary clinical criteria for idiopathic PD (Hughes *et al.*, 2001).

In the case of our patients, the diagnosis of idiopathic PD was originally posed on the basis of the positive family history, the unilateral onset of parkinsonian symptoms, and the lack of atypical signs. Thus, DAT-Scan examination was performed with the aim to identify the damage of the dopamine nigrostriatal terminals. Indeed, the reduction of tracer binding was found in the striatum contralateral to the clinical symptoms, further supporting the diagnostic suspicion. However, careful analysis of the first DAT-Scan images (Fig. 1a) allows the identification of a few atypical aspects : first, the tracer binding in the left striatum was, to our opinion, suggestive of structural compression and dislocation rather than degenerative damage of the nigrostriatal terminals, since the entire striatum (caudate and putamen nuclei) was poorly visualized, and there was a slight shift of the median line structures ; second, the contralateral striatum appeared completely normal, whereas DAT-Scan images in the early stages of PD often show the initial reduction of tracer binding also in the putamen ipsilateral to the clinical symptoms (Antonini and De Notaris, 2004). Antiparkinsonian therapy with pramipexole was, however, initiated, with slight improvement of the hemiparkinsonian symptoms, together with the occurrence of distal limb edema, slowness of thinking and sleep attacks. It is notable that all these accessory symptoms are known side-effects of pramipexole administration (Moller and Oertel, 2005). Therefore, on the second out-patient examination, pramipexole was withdrawn and levodopa/carbidopa therapy was initiated.

When the patient came to our observation, the lack of efficacy of the antiparkinsonian therapy and the occurrence of atypical signs urged further inves-

tigation by means of structural neuroimaging, that allowed the identification of the tumor.

As mentioned previously, supratentorial or infratentorial neoplasms are rather uncommon causes of parkinsonism. In a large series of 907 patients with supratentorial tumors sparing the basal ganglia, 0.3% presented with parkinsonism (Krauss *et al.*, 1995). Tumors of the frontal, parietal, and temporal area may present with parkinsonism (Krauss *et al.*, 1995 ; Salvati *et al.*, 2000). Furthermore, brainstem and third ventricle structural lesions can produce parkinsonism (Yoshimura *et al.*, 2002). Although parkinsonism can develop in association with any type of brain tumor, meningiomas are the most common neoplasms associated with parkinsonism, especially the parasagittal ones as well as those located in the sphenoid ridge and frontoparietal areas (Krauss *et al.*, 1995).

Compression of the basal ganglia and/or the nigrostriatal pathway and tumor infiltration of the striatum have been proposed as pathogenetic mechanisms of parkinsonism caused by intracranial neoplasms (Krauss *et al.*, 1995 ; Adhiyman and Meara, 2003). Parkinsonism due to brain tumors generally does not respond to antiparkinsonian drugs, and only surgical excision of the tumor may reduce or abolish the symptoms (Krauss *et al.*, 1995 ; Salvati *et al.*, 2000). In our case, the rapid reversal of the hemiparkinsonism after surgery and the normalization of the DAT-Scan performed 6 months after surgery indicate that compression of the basal ganglia by the edema surrounding the lesion was directly responsible for the parkinsonian symptoms.

In conclusion, the present case confirms that structural neuroimaging should be performed in any case of parkinsonism even when the clinical criteria are fulfilled and functional neuroimaging study suggest the asymmetric damage of the dopamine nigrostriatal pathway.

REFERENCES

- ADHIYMAN V., MEARA J. Meningioma presenting as bilateral parkinsonism. *Age and Ageing*, 2003, **32** : 456-458.
- ANTONINI A., DE NOTARIS R. PET and SPECT functional imaging in Parkinson's disease. *Sleep Med.*, 2004, **5** : 201-206.
- BENAMER T. S., PATTERSON J., GROSSET D. G., BOOIJ J., DE BRUIN K. *et al.* Accurate differentiation of parkinsonism and essential tremor using visual assessment of [¹²³I]-FP-CIT SPECT imaging : the [¹²³I]-FP-CIT study group. *Mov. Disord.*, 2000, **15** : 503-510.
- BONIFATI V., OOSTRA B. A., HEUTINK P. Unraveling the pathogenesis of Parkinson's disease – the contribution of monogenic forms. *Cell. Mol. Life Sci.*, 2004, **61** : 1729-50.
- HUGHES A. J., DANIEL S. E., KILFORD L., LEES A. J. Accuracy of clinical diagnosis of idiopathic Parkinson's disease : a clinico-pathological study

- of 100 cases. *J. Neurol. Neurosurg. Psychiatry*, 1992, **55** : 181-184.
- HUGHES A. J., DANIEL S. E., LEES A. Improved accuracy of clinical diagnosis of Lewy body Parkinson's disease. *Neurology*, 2001, **57** : 1497-1499.
- KLOCKGETHER T. Parkinson's disease : clinical aspects. *Cell Tissue Res.*, 2004, **318** : 115-120.
- KRAUSS J. K., PADUCH T. H., MUNDINGER F., SEEGER W. Parkinsonism and rest tremor secondary to supratentorial tumours sparing the basal ganglia. *Acta Neurochir.*, 1995, **133** : 22-29.
- MOLLER J. C., OERTEL W. H. Pramipexole in the treatment of Parkinson's disease : new developments. *Exp. Rev. Neurother.*, 2005, **5** : 581-586.
- SALVATI M., FRATI A., FERRARI P., VERRELLI C., ARTIZZU S. *et al.* Parkinsonian syndrome in a patient with pterional meningioma : case report and review of the literature. *Clin. Neurol. Neurosurg.*, 2000, **102** : 243-245.
- SELLBACH A. N., BOYLE R. S., SILBURN P. A., MELLICK G. D. Parkinson's disease and family history. *Parkinsonism Rel. Disord.*, 2006, **12** : 399-409.
- YOSHIMURA M., YAMAMOTO T., ISO-O N., IMAFUKU I., MOMOSE T. *et al.* Hemiparkinsonism associated with a mesencephalic tumor. *J. Neurol. Sci.*, 2002, **197** : 89-92.

Prof. Francesco E. PONTIERI,
Movement Disorder Unit, Sant' Andrea Hospital,
II Facoltà of Medicine, University 'La Sapienza',
Via di Grottarossa, 1035,
00189 Rome (Italy).
E-mail : francesco.pontieri@ospedalesantandrea.it