



## Incidental hemangioblastoma of the filum terminale

I. G. SERGIDES<sup>1</sup>, K. L. WAINWRIGHT<sup>2</sup> and M. BIGGS<sup>1</sup>

<sup>1</sup>Department of Neurosurgery, <sup>2</sup>Department of Radiology, Royal North Shore Hospital, Sydney, Australia

### Abstract

*Filum terminale hemangioblastoma is an extremely rare tumour with only a few case reports in the literature. The natural history is unknown but benign as well as more aggressive presentations have been reported. The authors present the first such lesion discovered incidentally and discuss the available literature.*

**Key words :** Hemangioblastoma ; filum terminale ; cauda equina ; incidental.

### Introduction

Hemangioblastomas of the filum terminale are exceptionally rare tumors. Previous clinical presentations have included low back pain, radiculopathy and even partial cauda equina syndrome (Wolbers *et al.*, 1985, Nadkarni *et al.*, 2006). We report the first case of such a lesion discovered incidentally.

### Case report

A 75 year old man presented to his family doctor complaining of general malaise and lethargy for 6 months. He had no specific symptoms and clinical examination was normal. He had no back pain. MRI of his cranio-spinal axis revealed a solitary homogeneously enhancing lesion with well demarcated margins within the cauda equina behind the body of L3 (Fig. 1a).

It was felt that the lesion should be surgically removed, largely because of its uncertain significance. A laminectomy was performed from L2-4 and a classical 'cherry-red' lesion was found adherent to the filum terminale (Fig. 1b). A feeding artery and vein were seen entering the tumor along the filum terminale from above. The tumor was removed 'en bloc' by dividing the filum above and below. The tumor measured 1.4 × 1.3 × 1.1 cm and demonstrated the typical microscopic pattern of numerous

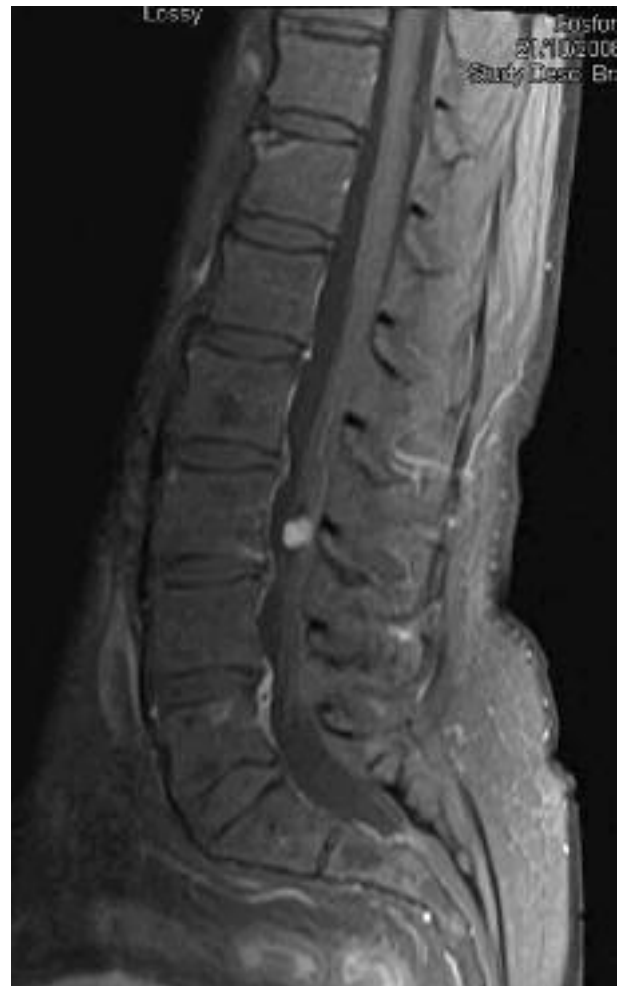

FIG. 1a. — T1 weighted gadolinium-enhanced sagittal MRI of the lumbar spine showing avid homogeneous enhancement of the lesion. This should raise the suspicion of a possible vascular tumor.

plexiform anastomosing capillary channels on reticulin staining. The patient suffered no complications.

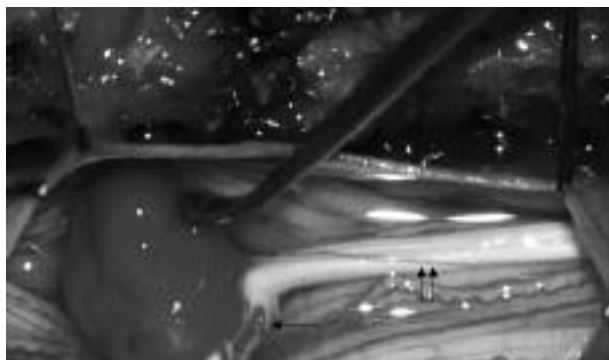


FIG. 1b. — Intra-operative photograph showing the classic cherry-red appearance of a hemangioblastoma. A feeding artery is seen entering the lesion superiorly (arrow). The lesion's intimate relationship with the filum terminale (double arrow) can be seen.

### Discussion

The term 'hemangioblastoma' was coined by Harvey Cushing and Percival Bailey in 1928 in the book 'Tumors Arising from the Blood-Vessels of the Brain'. The first report of such a lesion in the filum terminale was in 1943 by Wyburn-Mason (Wyburn-Mason, 1943) in a 25 year-old woman with radicular pain. Since then there have been only 6 other reported cases in the literature, all presenting with back pain or nerve root compression. Hemangioblastomas are notoriously vascular structures, a quality which means they may enlarge (Ortega-Martinez M. *et al.*, 2007) or bleed profusely during surgical resection. As a consequence previous authors have performed pre-surgical embolisation via the anterior spinal artery when these lesions have been discovered in the cauda equina (Biondi *et al.*, 2005 ; Nadkarni *et al.*, 2006). All reported cases of hemangioblastoma of the filum terminale have resulted in uncomplicated total surgical excision without neurological deficit whether embolised pre-operatively or not. Some have reported 'easy' removal of such tumors with minimal blood loss (Tibbs 1999, Biondi 2005). Surgical excision in our case was similarly straightforward. Asymptomatic lesions present a dilemma. The rarity of this condition precludes a comprehensive understanding of its natural history. Tibbs *et al.* reported a case of filum terminale hemangioblastoma which

had partially eroded the superior articulating processes of the L2 vertebra bilaterally causing back pain, suggesting the lesion had been present for a very long time (Tibbs *et al.*, 1999). Other authors have described a more malevolent history with partial cauda equina syndrome (Wolbers *et al.*, 1985 ; Nadkarni *et al.*, 2006). The avid enhancement on MRI should raise suspicion of this pathology and alert the surgeon to be prepared for a vascular lesion.

### Conclusion

The authors advocate surgical excision for this lesion in patients fit for surgery. Pre-operative embolisation is not necessary, but may be useful for intramedullary hemangioblastomas of the conus or spinal cord.

### REFERENCES

- BIONDI A., RICCIARDI G. K., FAILLOT T., CAPELLE L., VAN EFFENTERRE R. *et al.* Hemangioblastomas of the lower spinal region : report of four cases with pre-operative embolisation and review of the literature. *AJNR*, 2005, **26** (4) :936-945.
- NADKARNI T. D., MENON R. K., DESAI K. I., GOEL A. Hemangioblastoma of the filum terminale. *J. Clin. Neurosci.*, 2006, **13** (2) : 285-288.
- ORTEGA-MARTINEZ M., CABEZUDO J. M., FERNANDEZ-PORTALES I., PINEDA-PALOMO M., RODRIGUEZ-SANCHEZ J. A. *et al.* Multiple filum terminale hemangioblastomas symptomatic during pregnancy. Case report. *J. Neurosurg. Spine*, 2007, **7** (2) : 254-8.
- TIBBS R. E. Jr., HARKEY H. L., RAILA F. A. Hemangioblastoma of the filum terminale : case report. *Neurosurgery*, 1999, **44** (1) : 221-223.
- WOLBERS J. G., PONSSEN H., KAMPHORST W. Hemangioblastoma of the cauda equine. *Clin. Neurol. Neurosurg.*, 1985, **87** (1) : 55-59.
- WYBURN-MASON R. The Vascular Abnormalities and Tumours of the Spinal cord and its membranes. London, Henry Kimpton, 1943, pp 1-196.

Ioannis SERGIDES,  
18/1 Waruda st,  
Kirribilli,  
NSW 2061,  
Sydney (Australia).  
E-mail : ysergides@hotmail.com