



A case with a rare type of trigemino-oculomotor synkinesis: clinical and blink reflex study

H. BALABAN, Ö. K. YILDIZ, S. ELIAÇIK, E. BOLAYIR and S. TOPAKTAŞ

Department of Neurology, Cumhuriyet University School of Medicine, TR-58140 Sivas, Turkey

Abstract

Several abnormal synkinetic eye movements during jaw movements may often be seen after trauma or congenitally in the Marcus Gunn jaw winking phenomenon. The most frequent type consists of unilateral ptosis and retraction of the ptotic lid upon moving the jaw. The authors describe a case with isolated simultaneous adduction of the left eye upon jaw movement. This paper presents a rare case of Marcus Gunn jaw winking with trigemino-oculomotor synkinesis.

Key words: Cranial nerve synkinesis; Marcus Gunn Jaw Winking Phenomenon; blink reflex.

Introduction

Ocular aberrant synkinesis syndromes are a complex group of disorders involving abnormal miswiring of cranial nerves to the extraocular and jaw muscles. Marcus Gunn jaw-winking phenomenon (MGJWP) is a rare synkinetic syndrome characterized by retraction of the ptotic eyelid with jaw movements (1). MGJWP is considered to result from an aberrant connection between the branch of the trigeminal nerve supplying the pterygoid muscles and the oculomotor nerve (2-4).

Although MGJWP typically presents with eyelid retraction upon jaw movements, a number of variant forms have also been reported (5-7).

Case report

A sixty-year-old woman was admitted to our clinic because of the double vision that began abruptly twenty days earlier. She reported that double vision was induced by eating or chewing. The patient's past medical history was remarkable for arterial hypertension. She denied any ocular disease or abnormalities. Family history was noncontributory.

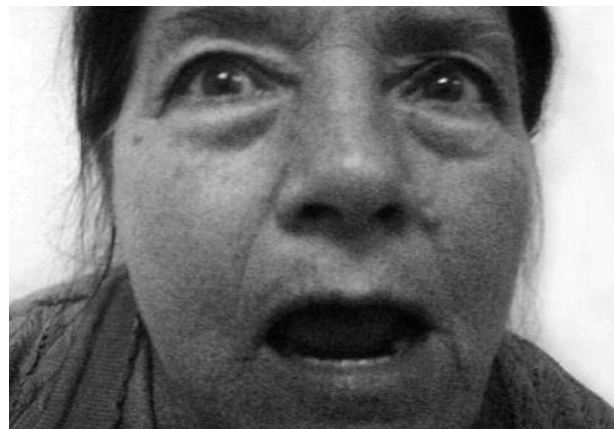

FIG. 1. — Adduction of the left eye with jaw opening

On admission neurological examination showed simultaneous adduction of the left eye when the patient opened her mouth wide (Fig. 1). Adduction of the left eye did not induce an eyelid retraction. Visual acuity was 20/20 in both eyes with normal fundoscopic appearance. The pupils were isocoric and equally reactive to light and accommodation. Conjugate eye movements in all directions were also normal. Ptosis, eyelid retraction or nystagmus were not observed. Other aspects of the neurological examination were normal.

Magnetic resonance (MR) images of the brainstem was normal. Blink reflex analysis after right and left supraorbital stimulation showed normal latencies and amplitudes of the ipsilateral R1 and the contralateral R1 and R2 components (Fig. 2).

The diagnosis of trigemino-oculomotor synkinesis of the left eye was made based on the observation of abnormal adduction of the left eye during jaw opening despite the absence of eyelid retraction.

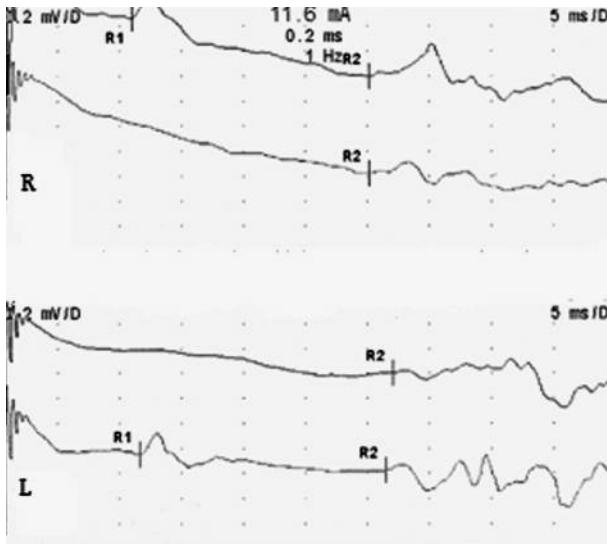


FIG. 2. — Blink reflex study. Supraorbital nerve stimulation on both sides elicited R1 and R2 components of normal latency and amplitude.

Discussion

Our patient presented with a left trigemino-oculomotor synkinesis. We suggest that isolated adduction of the left eye without accompanying eyelid retraction induced by jaw movements indicates a restricted form of the trigemino-oculomotor synkinesis phenomenon. An abnormal wiring or contact between the trigeminal nerve and the inferior division of the oculomotor nerve that supplies the medial rectus muscle should be the responsible mechanism underlying this rare type of MGJWP.

The term of synkinesis refers to a simultaneous movement or a coordinated sequence of movements of muscles which are supplied by different nerves or by separate peripheral branches of the same nerve (1). The most frequent synkinesis is facial synkinesis which occurs after Bell's palsy. MGJWP and Duane retraction syndrome are infrequent synkineses characterized by interconnections between different cranial nerves (8). Cross-talk occurs between the oculomotor and the abducens nerves in Duane syndrome and between the trigeminal and the oculomotor nerves in MGJWP (1, 7, 8). Synkinesis of cranial muscles may be acquired, congenital or also familial (6, 8, 9, 10).

MGJWP is thought to result from misdirection of a branch of the trigeminal nerve to the levator palpebrae muscle (7, 10). MGJWP typically consists of unilateral ptosis and retraction of the ptotic eyelid during jaw movements. Variant forms of the disorder

have also been reported. Trigemino-oculomotor synkinesis of the inferior division of the oculomotor nerve was previously reported by Kassem and Kodsí (7). However, their patient had eyelid retraction in addition to adduction and depression of the eye with jaw movements. Our patient presented with isolated adduction of the left eye without accompanying eyelid retraction. Although Mohan and Saroha (11) also described a patient with involuntary adduction of the eye with jaw movements, the authors reported that the patient had this synkinesis since birth. Therefore, to the best of our knowledge, acquired trigemino-oculomotor synkinesis consisting of isolated eye adduction upon jaw movement has not been reported before.

Trigemino-oculomotor synkinesis may occur congenitally or secondary to trauma. Our patient's past medical history was remarkable for neither of these conditions. There were no detectable ischaemic areas in the brainstem, but microinfarcts undetected by MRI could have been etiologic factors. The results of the blink reflex study indicated that the left trigeminal nerve was functionally normal. We hypothesize therefore that partial damage to the branch of the oculomotor nerve supplying the medial rectus muscle may have caused aberrant reinnervation by the trigeminal nerve. Theoretically, a possible explanation for the sudden onset of the symptoms could be a silent and occult interneuronal connection at the brainstem level that could have been activated after the occurrence of the oculomotor nerve damage.

From a practical point of view, a detailed examination of eye movements during jaw movements is necessary in patients presenting with diplopia in order to detect the presence of the various types of trigemino-oculomotor synkineses, even in elderly patients.

REFERENCES

1. Siatkowski RM, Glaser JS. Pediatric neuroophthalmology: general considerations and congenital motor and sensory anomalies. In: Neuro-Ophthalmology. Glaser JS, ed. Philadelphia, Lippincott, Williams and Wilkins, 1999, 461-488.
2. Duke-Elder S. Normal and abnormal development: congenital deformities. In: System of Ophthalmology. St. Louis, Mosby, 1963, 900-905.
3. Beard C. Types of ptosis. In: Ptosis. Beard C, ed. St. Louis, Mosby, 1981, 39-76.
4. Sargent JC. Nuclear and infranuclear ocular motility disorders'. In: Walsh and Hoyt's Clinical Neuroophthalmology. Miller NR, Newman NJ, eds. Baltimore, Lippincott Williams and Wilkins, 2005, 969-1040.

5. Oesterle CS, Faulkner WJ, Clay R, Folk ER, Lucchese N. *et al.* Eye bobbing associated with jaw movement. *Ophthalmology*. 1982;89:63-67.
6. Khan AO. Ptotic lid elevation during contralateral head tilt. *JAAPOS*. 2007;11:297-299.
7. Kassem IS, Kodsı SR. Marcus Gunn jaw winking with trigemino-oculomotor synkinesis of the inferior division of the oculomotor nerve. *J AAPOS*. 2009;13:315-316.
8. Khan AO, Al-Hommaıdı A, Al-Tukmani S. Familial ptotic lid elevation during ipsilateral abduction. *JAAPOS*. 2004;8:571-575.
9. Kodsı S. Marcus Gunn jaw winking with trigemino-oculomotor synkinesis. *J AAPOS*. 2000;4:316-317.
10. Koelsch E, Harrington JW. Marcus Gunn jaw winking synkinesis in a neonate. *Movement Disord*. 2007;22:871-873.
11. Mohan K, Saroha V. Congenital unilateral adduction associated with jaw movement: a rare variant of trigemino-oculomotor synkinesis. *J Pediat Ophth Strab*. 2004;41:174-176.

H. Balaban, M.D.,
Department of Neurology,
Cumhuriyet University School of Medicine,
58140 Sivas (Turkey).
E-mail: haticebalaban@yahoo.com