



Coexistence of ankylosing spondylitis and multiple sclerosis

Pinar BORMAN¹, Figen TUNCAY¹, Mine KÖYBAŞI¹, Ufuk ERGUN² and Levent INAN²

¹Ankara Training and Research Hospital, Clinic of Physical Medicine and Rehabilitation, Ankara, Turkey;

²Ankara Training and Research Hospital, Clinic of Neurology, Ankara, Turkey

Abstract

Ankylosing spondylitis is reported to involve not only the joints but neurologic systems as well. The association of MS and AS has rarely been reported in the literature and epidemiological studies did not prove a definite relationship between these two conditions at present.

We here describe a HLA-B 27 positive AS patient with MS symptoms and review the literature on the association of two diseases.

Key words: Ankylosing spondylitis; multiple sclerosis; neurological complications.

Introduction

Ankylosing spondylitis (AS) is a chronic inflammatory rheumatic condition, primarily affecting the axial skeleton and large peripheral joints. The disease is characterized by low back pain, limitation of spinal mobility and radiological evidence of sacroiliitis and spondylitis, and can be associated with extra-articular involvement including several neurological symptoms (1). The neurologic complications of AS are rare and include single root lesions, monophasic myelopathy, spinal cord compression due to atlanto-axial subluxation or fracture of stiff vertebrae, cauda equina syndrome and rarely multiple sclerosis (MS) or MS-like syndrome (2).

The cause of MS remains unknown. There is evidence for an environmental trigger coupled with genetic susceptibility contributing to MS development (3). The association of MS and AS has rarely been reported in the literature and epidemiological studies did not prove a definite relationship between these two conditions at present (4).

We report a HLA-B 27 positive AS patient with MS symptoms and review the literature on the association of these two diseases.

Case Report

A 34-year-old man known with a 15-year history of AS; presented to the outpatient clinic of physical medicine and rehabilitation with difficulty in walking and balance, increased leg muscle tone and fatigue. He also complained of difficulty voiding, constipation and decreased libido. He mentioned that his symptoms had begun more than one year ago but had progressed over the last 6 months. His medical history was positive for uveitis, left total hip arthroplasty 5 years ago and upper gastrointestinal tract bleeding 4 months ago. He was on sulfasalazin 2 g/day and 150 mg/day indomethacin with a proton pump inhibitor. He denied having fever. He was not smoking and not drinking alcohol.

On physical examination his vital signs were normal. Mobility of lumbar and thoracic spine, bilateral hips and shoulders was markedly reduced and he had a kyphotic posture. Radiologic examination revealed grade 4 sacroiliitis and complete ankylosis of the dorso-lumbar spine. Modified Schober test was 1 cm, a chest expansion test was 2 cm. The distance from ground to finger was 40 cm, the wall to tragus 36 cm, the distance between two malleoli was 47 cm. General joint pain intensity by VAS was 40 cm. The Bath Ankylosing Spondylitis Disease Activity Index (BASDAI), The Bath Ankylosing Spondylitis Metrology Index (BASMI) and the Bath Ankylosing Spondylitis Functional Index (BASFI) were 3.8, 8 and 96 respectively. The neurological examination revealed hyperactivity of all reflexes and positivity of pathologic reflexes. Bilaterally spastic paraparesis in lower extremities and an intentional tremor of upper extremities were recorded. There was no sensational abnormality and Romberg test was negative.

Routine complete blood, biochemical tests, and tests for tumour markers, vitamin B12 level and

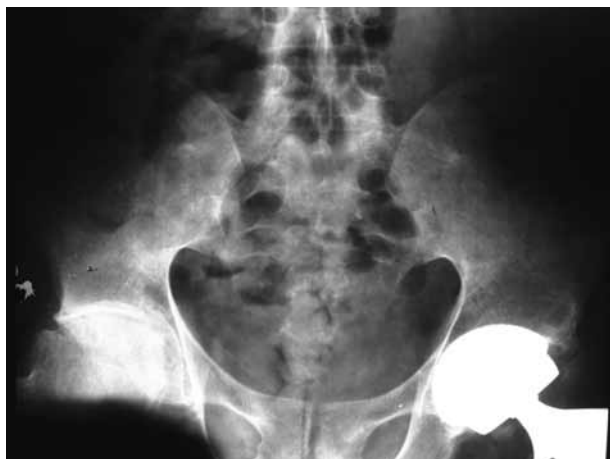

FIG. 1. — Pelvic x-ray showing bilateral grade 4 sacroileitis and hip involvement on right side and total hip arthroplasty in the effect side.

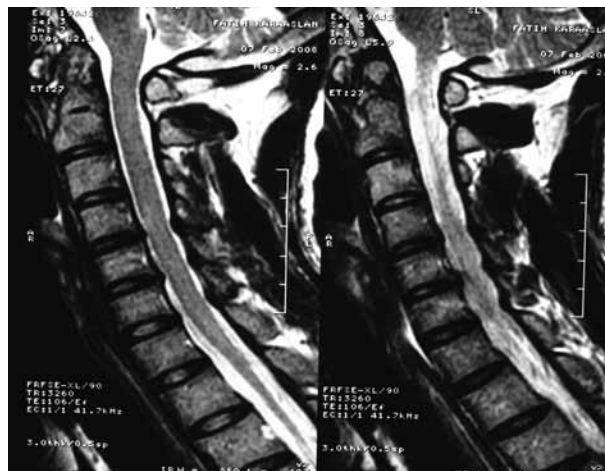

FIG. 3. — MRI of cervical spine showing focal centromedullar high intensity at C4-5.

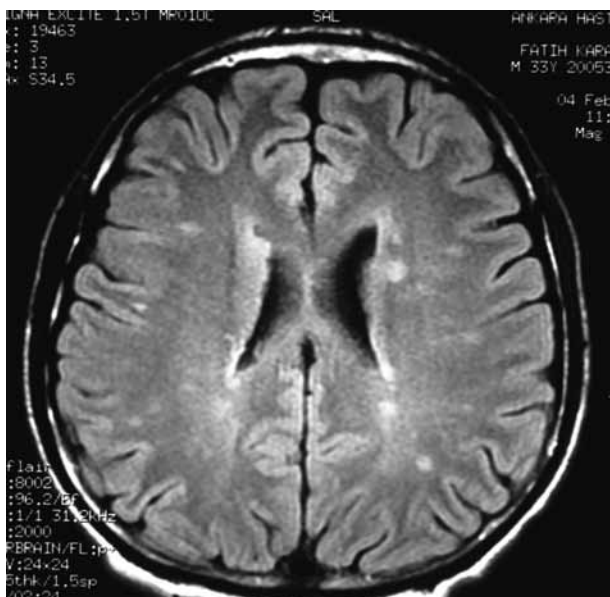


FIG. 2. — Cranial magnetic resonance imaging. T2 weighed images. Multiple foci of increased signal intensity in the periventricular white matter and cerebellar hemispheres (transvers view).

thyroid functions were in normal ranges. Erythrocyte sedimentation rate and C-reactive protein were 64 mm/h and 8.35 mg/dl respectively. Serological tests for Brucella, HIV and hepatitis were negative. HLA-B27 was positive.

There was microscopic hematuria in complete urine analysis. Urodynamic evaluation showed hyperkinetic neurogenic bladder.

Lumbar puncture (LP) could not be performed due to the limitation and ankylosis of the lumbar

spine. Pelvic X-ray showed bilateral sacroileitis and total hip arthroplasty in the effect side (Fig. 1). Brain Magnetic Resonance Imaging (MRI) showed multiple foci of increased signal intensity in the periventricular and subcortical white matter bilaterally (Fig. 2). Spine MRI showed focal centromedullar high intensity at C4-5 (Fig. 3), suggesting a demyelinating disease process. Visual evoked potential (VEP) latencies were prolonged bilaterally (P 100 latency for the right eye: 128.1 msec, for the left eye: 127.8 msec), somatosensory evoked potential (SEP) latencies were prolonged at the right tibial posterior nerve (P1: 45.8 msec, P2 66.9 msec) and absent at left and right tibial posterior nerves (P1:0, P2:0). The third wave of the brain stem auditory evoked potential (BAEP) was also prolonged (right III: 4.00 msec, left III: 4.24 msec) on both sides.

Discussion

A number of AS cases presenting with possible or definite MS have been reported in the English literature (5-12). Libbrecht and De Bleecker (7) reviewed the literature for the association of AS and MS or MS-like conditions and reported 9 cases before their case, in which only 4 of them had definite MS. Since then, 6 cases were reported and only 3 had a diagnosis of definite MS (Table 1). This illustrates that the association of AS and definite MS is very rarely reported in the literature. In all reported cases, AS preceded the first signs of MS. The intervals between two conditions ranged from 3-21 years. In most of the earlier cases, information was missing about clinical, radiologic or cerebrospinal fluid (CSF) findings consistent with MS, due to the

Table 1

The literature review about the association of MS and AS, reported in the last 10 years

	Thomas (2)	Hanrahan (1)	Libbrecht (1)	Uysal (1)	Cellerini (1)	Khan (2)	Math-hews (1)	Whitman (1)	Present case
Age at onset of AS	17,17	24	*	31	42	17,20	*	*	19
Age at onset of MS	21,26	43	40	41	57	38,25	46	*	34
Sex	M,M	F	F	M	F	M,M	M	*	M
HLA B 27	*,*	+	+	-	+	*,*	*	+	+
Neurological diagnosis	MS, MS	Definite MS	Possible MS	Definite MS	Definite MS	Definite MS	Definite MS	MS	Definite
Clinical findings	+,+	+	+	+	+	+,+	+	+	+
Radiological findings (MRI -CT/myelogram/necropsy)	*,*	*	spine abn	abn	abn	N,*	abn (N)	+	+
VEP	*,*	abn		abn	*	*,*	*	*	abn
SEP	*,*		N	abn	*	*,*	*	*	abn
BAEP	*,*	N	N	abn	*	*,*	*	*	abn
CSF	+, *	*	N	abn	abn	abn/*N	N	*	*

AS; ankylosing spondylitis, MS; multiple sclerosis
 abn; abnormal, N; normal
 * not identified.

ancient and incompetent technology. In the very early cases shown in the Table 1, the only abnormality in CSF was the increased CSF protein level. In all these cases the diagnosis was based on clinical relapsing and remitting nature of the findings. We have described a patient with longstanding AS who developed progressive spastic paraparesis with clinical symptoms and cerebral MRI findings suggesting MS. In our case, AS also preceded the first signs of MS, similar to previous reports. Our case was HLA-B 27 positive and represents a definite MS case based on clinical, radiological and electrophysiological findings, which is different from most of the previous reports containing limited information. However, we could perform a lumbar puncture in our patient because of the rigid spine and could therefore not show an oligoclonal band in CSF. However VEP and SEP were all abnormal in our patient and MS was defined according to the revised criteria of McDonald (13).

Both AS and MS share an yet unclear etiopathogenesis. Immunologic studies showed that HLA A3, B7, DR3 and Dw2 haplotypes are increased in MS patients. Only the increased prevalence of HLA B7 haplotype is common to both MS and AS (7), and evidence of cross reactivity of HLA B27 with HLA B7 has been reported (14). In our case, HLA B7 haplotype was not present. Molecular mimicry and antigen induced activation of T lymphocytes is also involved in both diseases. The new concept of molecular mimicry is a general term based on T cell

degeneracy. Activation of T lymphocytes is concerned in both diseases, although there is no evidence of a common favoring factor and the antigenic stimulus remains unknown for both diseases (7). Absence of complete concordance of disease expression of both AS and MS suggests that environmental factors may play a role in both diseases but still the etiopathogenesis of the association of these two diseases needs to be illuminated (14).

Sufficient evidence does not seem to be available to support a true association of AS and MS. Pillay and Hunter reported an increased prevalence of abnormal evoked potentials in AS patients suggesting an association with MS-like disease and AS (15). On the other hand, Hanrahan *et al.* (6) investigated the prevalence of HLA-B27 in patients with MS and indicated not only a higher incidence of HLA B27 positivity but also sacroiliitis. Although they could not indicate an abnormality in VEP, BAEP and SEP except some minor peripheral abnormalities in their study group, these results may also indicate a strong association between AS and MS. We believe that future studies will bring vigorous evidence highlighting the association of these two conditions.

In conclusion, definite MS may be a separate neurological manifestation associated with AS and the coexistence of AS and MS can occur at a much higher incidence than might be expected. Future studies are needed for sufficient evidence indicating the relationship between these suffering diseases.

REFERENCES

1. van der Linden S, van der Heijde D. Spondyloarthropathies. In: Ruddy S, Haris ED, Sledge CB, eds. Kelley's Textbook of Rheumatology 6th ed. Philadelphia: W.B. Saunders Company; 2001. p. 1039-53.
2. Oh DH, Jun JB, Kim HT, Lee SW, Jung SS, Lee IH. *et al.* Transvers myelitis in a patient with long-standing ankylosing spondylitis. *Clin Exp Rheumatol.* 2001;19:195-6.
3. Lynch SG, Rose JW. Multiple sclerosis. *Dis Mon.* 1996;42:1-55.
4. Calin A. Is there an association between ankylosing spondylitis and multiple sclerosis? *Ann Rheum Dis.* 1989;48:971-2.
5. Thomas DJ, Kendall MJ, Whitfield AG. Nervous system involvement in ankylosing spondylitis. *Br Med J.* 1974;1:148-50.
6. Hanrahan PS, Russel AS, McLean DR. Ankylosing spondylitis and multiple sclerosis: an apparent association? *J Rheumatol.* 1988;15:1512-4.
7. Libbrecht N, De Bleecker J. Ankylosing spondylitis and multiple sclerosis *Acta Clinica Belgica.* 1999;54-1.
8. Tan FU, Tellioglu S, Aydın G, Erdemoğlu AK, Keleş I. Ankylosing spondylitis and multiple sclerosis in an HLA-B27 negative patient. *Acta Neurol Belg.* 2004;104:169-72.
9. Cellerini M, Gabbrielli S, Bonghi SM. Cerebral magnetic resonance imaging in a patient with ankylosing spondylitis and multiple sclerosis-like syndrome. *Neuroradiology.* 2001;43:1067-9.
10. Khan MA, Kushner I. Ankylosing spondylitis and multiple sclerosis: A possible association. *Arthritis Rheum.* 1979;22:784-6.
11. Matthews WB. The neurological complications of ankylosing spondylitis. *J Neurol Sci.* 1968;6:561-73.
12. Whitman GJ, Khan MA. Unusual occurrence of ankylosing spondylitis and multiple sclerosis in a black patient. *Cleve Clin J Med.* 1989;56:819-22.
13. Polman CH, Reingold SC, Edan G, Filippi M, Hartung HP, Kappos L. *et al.* Diagnostic criteria for multiple sclerosis: 2005 revisions to the "McDonald Criteria". *Ann Neurol.* 2006;59:727-8.
14. Ebers GC, Bulman DE, Sadovnick AD, Paty DW, Warren S, Hader W. *et al.* A population-based study of multiple sclerosis in twins. *N Engl J Med.* 1986;315:1638-42.
15. Dolan AL, Gibson T. Intrinsic spinal cord lesions in two patients with ankylosing spondylitis. *J Rheumatol.* 1994;21:1160-1.

Figen Tuncay, M.D.,
Associate Professor,
Ankara Training and Research Hospital,
Clinic of Physical Medicine and Rehabilitation,
Ankara, Turkey.
E-mail: figengokoglu@mynet.com